

## EAR COMPLICATIONS OF THE CRAWLING MAGGOTS

Abdul Basit Madni,<sup>1</sup> Muhammad Asim,<sup>2</sup> Maroof Aziz Khan<sup>3</sup>

### Abstract

**Objective:** To assess the different complications of maggots invasion into the human ear by examination under microscope (EUM).

**Study Design:** Prospective descriptive study.

**Settings:** Department of Otorhinolaryngology, Quaid-e-Azam Medical College, Bahawal Victoria Hospital, Bahawalpur.

**Duration of Study:** December 2012 to December 2013 (1 year).

**Material and Methods:** We collected all cases of maggots in the ear coming to the emergency and out-patient departments of Bahawal Victoria Hospital meeting the inclusion and exclusion criteria during the duration of the study. After the formal permission from the hospital ethical committee these cases were entered in the study and the successful treatment of the disease in the form of complete removal of all the maggots from the ear was achieved in the in-patient

department. After that we assessed the different complications produced by the maggots by doing examination under microscope. The findings were noted and recorded on a prescribed questionnaire.

**Results:** There were a total of twenty (20) cases with maggots in the ear. Ten patients were males and ten were females (50%). Fifteen patients (75%) were below five years of age, four patients (20%) were from six to ten years of age and one patient was above 11 years. All twenty patients (100%) gave the history of ipsilateral ear discharge and pain in the ear. Bleeding was present in seventeen patients (85%). Thirteen patients (65%) had hearing difficulty. Only one patient (5%) was mentally retarded. All patients (100%) belonged to poor socioeconomic class. One patient (5%) was having bilateral maggots in his ears. Excoriation of the skin of pinna was found in fourteen patients (70%), and one patient (5%) had skin loss of part of auricle. In the external auditory canal, ten patients (50%) had bruising and ten had skin ulceration (50%). Tympanic membrane perforation was found in thirteen patients (65%). Out of these thirteen patients with perforated drums, five patients (38.4%) were having middle ear granulations.

**Conclusion:** Maggots ear also known as aural myiasis involves poor malnourished children and young adults. It can be responsible for variable degree of damage to the structures of human ear causing important complications. Improving the hygiene, nutritional status and treating the underlying ear disease, this problem can be overcome easily.

**Key words:** Myiasis, maggots, ear discharge.

---

Madni A.B.<sup>1</sup>  
Registrar, Department of ENT and Head and Neck Surgery,  
Bahawal Victoria Hospital, Bahawalpur

Asim M.<sup>2</sup>  
Senior Registrar, Department of ENT and Head and Neck  
Surgery, Bahawal Victoria Hospital, Bahawalpur

Khan M.A.<sup>3</sup>  
Professor and Head of the Department of ENT and Head  
and Neck Surgery, Quaid-e-Azam Medical College /  
Bahawal Victoria Hospital, Bahawalpur

## Introduction

Maggots are larvae of different species of Diptera, also known as two winged houseflies.<sup>1</sup> For a considerable period of time these larvae take their feed from the dead or living tissue of the host like liquid body substances or food ingested.<sup>2</sup> Myiasis is a term used when these larvae infest and invade the skin and body tissues of humans or animals. Classification of myiasis is based on the type of human tissues invaded by the maggots like aural, nasopharyngeal, cutaneous, urogenital, intestinal and ophthalmomyiasis.<sup>3,4</sup>

Invasion by these maggots of the human ear is known as aural myiasis. We have collected the cases in which maggots are present in the external auditory meatus (EAM) causing infestation of its skin and deeper structures of ear. A gravid female is attracted by the odor of discharge coming out of the infected ear (usually pseudomonas). Female then deposits 200- 250 eggs within an interval of three days.<sup>5</sup> Larvae feed on the recipient proteinaceous tissue and pass through three stages before they wander out from the tissue. Usually it takes four to six weeks to complete the life cycle from egg to the adult but it is highly variable depending on the ambient temperature.<sup>5</sup> The maggots in the ear can produce clinical symptoms like blood stained aural discharge, intense pain, itching and sometimes vertigo and tinnitus.<sup>1</sup> In literature limited cases of human aural myiasis have been reported, involving the patients ranging from neonates to older age groups.<sup>6-8</sup> In Pakistan, only one study has been carried out by Imdad, et al, in 2006 establishing the risk factors of human aural myiasis in their setting.<sup>9</sup> In our study we collected all the cases of maggots ear (aural myiasis) in one year with the objective to assess the predisposing factors, age and gender distribution and clinical manifestations with complications by doing examination under high power operating ear microscope.

## Material and Methods

We did a prospective study and collected all cases of maggots in the ear coming to the out-patient and emergency departments of ENT from December 2012 to December 2013(1 year).

## Inclusion Criteria

All such patients who gave the history of maggots coming out of ears and confirmed on initial otoscopic

examination were included in the study. There was no age and gender restriction. All patients with unilateral and bilateral maggots ear (aural myiasis) were included.

## Exclusion Criteria

Those patients who gave the history of maggots coming out of their ears but otoscopic examination and suction clearance did not prove the presence of maggots were excluded from the study.

## Data Collection Tool and Technique

All patients meeting the above mentioned criteria were admitted in the in-patient department and their complete history was taken and recorded on the formulated questionnaire. Antibiotics were started after taking the pus for culture and sensitivity and later on modified in accordance with the report. Maggot oil containing chloroform and turpentine oil was used to treat the myiasis. Strip gauze packing soaked in maggot oil was placed in the affected ear three times a day and replaced after one hour of insertion followed by suction clearance. This process was continued until after consecutive three packings, no maggots were found by suction or manual picking. These patients were then examined under operating microscope (EUM) using short-term intravenous anesthesia if required. All the findings of EUM were noted and recorded on a questionnaire. SPSS version 10 was used as a statistical package for data analysis and frequency distribution. Patients were discharged after managing the myiasis and underlying ear disease if present.

## Results

According to the inclusion and exclusion criteria, twenty patients were included in the study. Ten patients were males and ten were females (50%). We made three groups of age. First group comprised of the patients below five years of age, second group was from six to ten years and the third group included the patients from eleven to fifteen years of age. Fifteen patients belonged to the first age group (75%), four patients were from the second age group (20%), and one patient belonged to the third group of age (5%) see chart 1. All twenty patients were from poor socioeconomic class (100%). Ear discharge and otalgia were present in all twenty patients (100%). Culture of the

discharge showed growth of pseudomonas aeruginosa in five patients (25%), staphylococcus aureus in seven patients (35%) and in eight patients (40%) no growth of microorganism was isolated after 72 hours. Seventeen patients complained of bleeding from the involved ear (85%). Hearing difficulty was present in thirteen patients (65%) reported by the parents and later on assessed by free field voice tests in the patients belonging to the first age group and tuning fork tests in the patients belonging to the other age group. Mental retardation was present in only one patient (5%). None of the patients complained of vertigo and facial weakness. Bilateral maggots ear were present in one patient only. After successful removal of all the maggots from the ear by conservative treatment and suction, all the patients were planned for examination under micro-

scope to see the damage and complications in the ear. The status of pinna, external auditory meatus (EAM), tympanic membrane and the middle ear were examined. Fourteen patients had excoriation of the skin of pinna (70%), and one patient had partial skin loss at antihelix (5%). Ten out of twenty patients were having bruised skin of EAM (50%), while ten patients developed ulceration of the skin of EAM (50%) see chart 2. Subtotal tympanic membrane perforation was seen in thirteen patients (65%) while seven patients were having intact tympanic membranes (35%) see chart 3. Five of the thirteen patients with tympanic membrane perforation were found to have middle ear granulations (38.4%) whereas remaining eight patients had normal middle ear mucosa (61.5%).

Age groups in the patients of maggots ear:

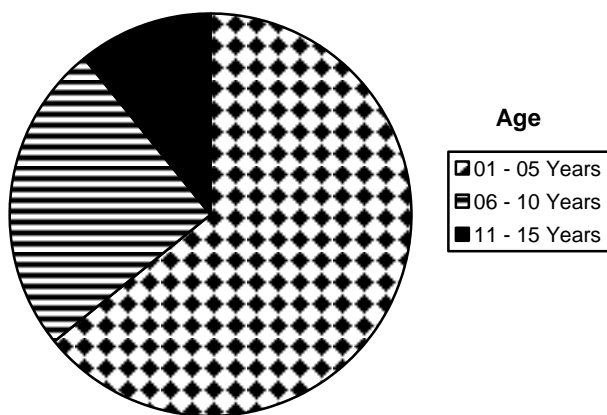


Chart 1: Status of external auditory meatus (EAM) in the patients of maggots ear.

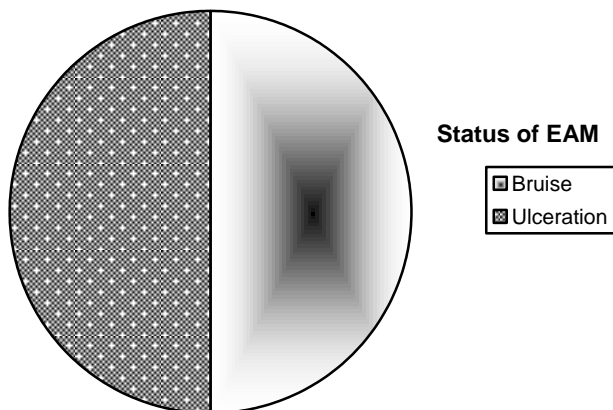


Chart 2: Status of the tympanic membrane (T.M) in the patients of maggots ear (Aural myiasis).

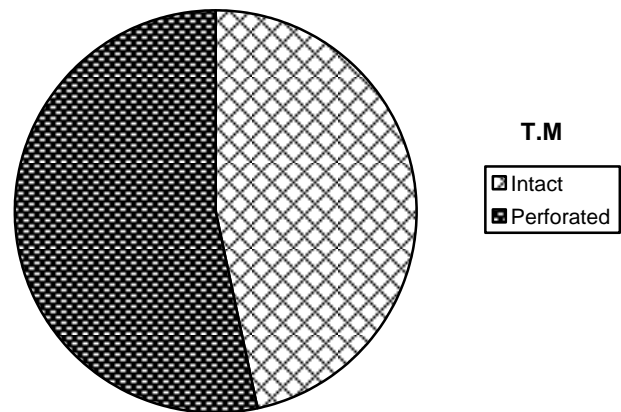


Chart 3: T.M was perforated in 65% of patients.

## Discussion

Maggots invasion is an uncommon clinical entity and not many cases of human aural myiasis are mentioned in the literature.<sup>10</sup> Different species of flies can be involved in the aural myiasis, depending on the climate and region. In the literature chronic discharging ear, poor socioeconomic status and mental retardation are the common risk factors for the maggots to infest the ear.<sup>9</sup> Maggots involving the ear usually cause foul smelling, blood stained ear discharge, intense pain and in few cases dizziness and tinnitus.<sup>1</sup> A rare life threatening condition can occur if these maggots access the brain through middle ear.<sup>11</sup> In our study, ear discharge, low socioeconomic living status and mental retardation were the predisposing factors. We can only identify ear discharge, pain, bleeding from the ear and hearing difficulty to be the important clinical features among the patients of aural myiasis in this study. Sin-

gh and colleagues in their retrospective study of 94 cases of childhood myiasis found 81.16% cases of aural myiasis and 96.8% of patients belonged to poor socioeconomic class.<sup>12</sup> Casanova – Roman, et al, found mental retardation and poor hygiene as the common predisposing factors.<sup>13</sup> Imdad, et al, in their prospective study established poor socioeconomic family status, chronic discharging ear and swimming in stagnant water as the common risk factors.<sup>9</sup> In our study only one patient was having bilateral maggots in the ear and this patient also had mental retardation. Bayindir and colleagues in 2010 also reported one child with bilateral maggots in the ear along with mental retardation.<sup>14</sup> Local inflammatory and malignant diseases along with senile debility and alcoholism can also be the additional predisposing factors.<sup>2,15</sup> We could not find any study in the literature, which has assessed the incidence of complications like ulceration, skin loss, tympanic membrane perforation and mucosal change in the middle ear produced by aural myiasis. Regarding the treatment of maggot ear, cleansing the ear with saline, chloroform, ethanol and hot water followed by suction or picking by microsurgical forceps are the recommended techniques.<sup>9,12-14,16</sup> Systemic and topical antibiotics are also given to cover secondary infection.<sup>13</sup> This study not only demonstrates the common conditions which may become the risk factors for developing maggots in the ear but also documents the residual clinical complications which usually persist even after the removal of all the maggots from the ear. Some of these complications are treatable like skin ulceration and loss while some may become permanent like tympanic membrane perforation. Further research is required to see the long-term outcome of these complications.

## Conclusion

Maggots ear also known as aural myiasis although a rarely occurring condition in most developed countries, is fairly common disease in most of the developing parts of the world. Chronic aural discharge, low living status, and mental retardation can be the causative factors. If not treated earlier maggots can damage the important structures of ear causing deafness and in case of access to the brain can become life threatening as well. Good health education, improvement in the socioeconomic status and early detection with treat-

ment of underlying chronic ear disease can markedly reduce both the occurrence and complications.

## References

1. Braveman I, Dano I, Saah D, Gapany B. Aural myiasis caused by flesh fly larva. *Sareophaga haemorrhoidalis*. *J Otolaryngol*. 1994 Jun; 23 (3): 204-205.
2. Kumarasinghe SP, Karunaweera ND, Ihalamulla RL. A study of cutaneous myiasis in Sri Lanka. *Int j Dermatol* 2000 Sep; 39 (9): 689-694.
3. Burns T, Breathnach S, Cox N, Griffiths C. Diseases caused by arthropods and other noxious animals. IN: *Rook's Textbook of Dermatology*. Malden, MA: Blackwell Publishing, 2004; Vol. 2. 7<sup>th</sup> ed.: 33.8-11.
4. Kettle DS. *Medical and veterinary Entomology*. Wallingford, UK: CAB International, 1990: p. 241-255.
5. Wall R, Shearer D. *Veterinary Entomology: arthropod ectoparasites of veterinary importance*. London: New York: Chapman and Hall, 1997: p. 238-243.
6. Lee HL, Young YK. Human aural myiasis. *South Asian J Trop Med Public Health*, 1991; 22: 274-275.
7. Rohela M, Jamaiah I, Amir L, Nissapatorn V. A case of auricular myiasis in Malaysia. *Southeast Asian L Trop Med Public Health*, 2006; 37 (suppl. 3): 91-94.
8. Koh TH. Neonatal myiasis: a case report and a role of the internet. *J Perinatol*. 1999; 19 (7): 528-529.
9. Imdad, Adnan Yar Mohammad, Mohammad Javed. Risk factors leading to aural myiasis. *J Postgrad Med Inst Dec*. 2006; 20 (4): 390-392.
10. Panu F, Cabras G, Contini C, Onnis D. Human auricular myiasis caudex by *Wohlfartia magnifica* (Schiner) (Diptera: Sarcophagidae): first case found in Sardinia. *J Laryngol Otol*. 2000 Jun; 114 (6): 450-452.
11. Markell EK, John DT, Krotoski WA. Arthropods and Human Disease. In: *Medical Parasitology*. Philadelphia: W. B Saunders, 1999: p. 357-388.
12. Singh I, Gathwala G, Yadav SP, Wig U, Jakhar KK. Myiasis in children: the Indian perspective. *Int J Pediatr Otorhinolaryngol*. 1993 Jan; 25 (1-3): 127-131.
13. Casanova – Roman MI, Sanchez – Legaza E, Sanchez – Porto A, Murga C. Aural myiasis in an infant. *Infez Med*. 2010 Sep; 18 (3): 175-176.
14. Bayindir T, Miman O, Miman MC, Atambay M, Saki CE. Bilateral aural myiasis (*Wohlfartia magnifica*): a case with chronic suppurative otitis media. *Turkiye Parazitolo Derg*. 2010; 34 (1): 65-67.
15. Cunningham DG, Zanga JR. Myiasis of the external auditory meatus. *J Pediatr*. 1974 Jun; 84 (6): 857-858.
16. Kaczmarczyk D1, Kopczynski J, Kwiecien J, Michalski M, Kurnatowski P. The human aural myiasis caused by *Lucilia sericata*. *Wiad Parazytol*. 2011; 57 (1): 27-30.