

EXPERIENCE OF HALOPELVIC TRACTION IN THE TREATMENT OF SEVERE SPINE DEFORMITY: A CASE SERIES

Syed Asif Ali,¹ Asad Ali Ch,² Ahmad Sarfraz Humayun,³ Usman Zafar Dar,⁴ Syed Muhammad Awais⁵

Abstract

Background: Severe and rigid scoliosis and kyphosis are difficult to treat but with the advent of new spinal operative techniques and implants, it has become manageable in expert hands. However these implants are too expensive for developing countries like us. The Halo-pelvic traction is a relatively cheaper device system used to treat such deformities. Moreover, rapid curve correction and one stage surgery may lead to permanent neurological deficit.

Objective: To evaluate treatment outcome of Halo-pelvic Traction in the treatment of severe scoliosis and kyphosis.

Methodology: This descriptive study was conducted in the department of Orthopedics surgery and traumatology unit – I, King Edward Medical University, Mayo Hospital Lahore from September 2010 to August 2012. The patients with severe spinal deformity which could not be corrected at a single stage were included. A Performa was made for each patient and results were statistically analyzed by using SPSS version 20.

Results: Total no. of 07 patients were treated, out of them 04 scoliosis patients having mean Cobb's angle of $77.25 \pm 5.31^\circ$ before treatment, improved significantly to $45 \pm 5.35^\circ$ after surgery ($p < 0.0001$), 03 kyphosis patients with mean Kyphus angle of $96.67 \pm 24.66^\circ$ improved to $58.33 \pm 17.56^\circ$ ($p < 0.0001$). Two major complications i.e. one paraplegia which recovered incompletely and one had CSF discharge from cranial pin that was also revived thoroughly after changing the position of the pin.

Conclusion: Halopelvic traction device can help in treating the patients of severe scoliosis and kyphosis.

Keywords: Kyphosis, Halo-Pelvic, Kyphus angle, Cobb's angle.

Ali S.A.¹

Associate Professor of Orthopaedic Surgery, Gujranwala Medical College, University Teaching Hospital Gujranwala

Ch. A.A.²

Assistant Professor / Visiting Faculty
Amna Inayat Medical College, Lahore

Humayun A.S.³

Senior Registrar, Department of Orthopaedic Surgery Unit-I
KEMU / Mayo Hospital, Lahore

Dar U.Z.⁴

Assistant Professor of Orthopaedic Surgery
Gujranwala Medical College, Gujranwala

Awais S.M.⁵

Chairman Department of Orthopaedic Surgery
KEMU / Mayo Hospital, Lahore

Introduction

Scoliosis is a spinal deformity that is three dimensional because it involves both angular and rotational

asymmetry of vertebrae and ribs. Kyphosis is an excessive dorsal curvature of spine i.e. in sagittal plane. Scoliosis may be idiopathic, congenital or secondary to some disease. Numerous potential etiologies of kyphosis have been recognized like TB spine, Scheuermann's disease, ankylosing spondylitis etc. These disorders influences roughly 1 in 1000 individuals, while around 1 in 10,000 affected people has a severe spinal deformity.¹⁻³

Conservative treatment is helpful in relief of painful scoliosis but it will not correct the deformity. When symptoms are not controlled by conservative management more truculent treatment may be obligatory.⁴ The technique of surgical treatment depends on the age of the patient, the type and size of the deformity, and the presence or absence of spinal cord compression causing a neurologic deficit.⁵

Halo-pelvic is a powerful and effective device. It is a type of external fixator used to distract and correct deformities of spine. It consists of Halo and pelvic components connected by 04 rods.^{6,7} Halo skeletal traction was first introduced by Perry and Nickel, 1959.⁸ De-Wald and Ray reported the pelvic halo in 1970.⁹ A controlled distraction and correction can be carried out for final procedure of spinal fusion. It has several advantages over other techniques like it can hold the neck or trunk better than meticulously molded plaster casts, jackets or spinal orthosis securely after correction of spinal deformities. Skeletal traction by skull calipers has been utilized for the cervical spine but this is only efficacious in one plane.^{8,9}

It can be used in patients with severe pulmonary restriction, pressure sores from a cast, soft tissue contractures, or inability to control pelvic tilt and rotation. It provides gradual and controlled forces. It has excellent results in treating severe, rigid spinal deformities.¹⁰ We made the device through our local resources to assess the outcome of surgery in the severe deformities of spine.

Materials and Methods

This descriptive study was conducted in seven patients having severe spinal deformities seeking for the correction of Scoliosis and Kyphosis and carried out during September 2010 to August 2012 within two years. Data was collected, surgery was performed and follow ups were made at department of orthopedic surgery and traumatology unit – I (DOST-I) / King Edward Medical University / Mayo Hospital Lahore.

The diagnosis was made by history, hospital treatment record, clinical features and X-ray appearance of the lesion.

Surgical Technique Anterior Spine Release

- In kyphosis apex was exposed by thoracotomy and osteotomy of body of apical vertebra performed.
- In scoliosis apex and adjacent vertebrae were exposed by thoracotomy from convex side and minimum three to maximum five discs excised. Rib was used as bone graft in the disc space.

Application of Halopelvic Traction

- Skull radiographs were used to assess the cortical thickness of the skull. 04 cranial pins were inserted in frontal and two in temporoccipital bone. Two locally manufactured pins threaded from the middle (like Denhem pin) were inserted in the iliac crest and two pins in posterior superior iliac spine.
- Halo and pelvic components were connected to the pins.
- 04 connector rods were linked with halo and pelvic component.
- 1 mm twice daily (slow) distraction started the next day of surgery which was increased to 2 – 5 mm (gradually) by daily assessing the neurology.
- Distraction was stopped or reversed in case of pain or numbness in the limbs.

Arthrodesis of Spine: After achieving a good correction a second stage surgery by the same thoracotomy approach was performed by placing a fibular graft in the bodies of vertebrae. In third stage traction was removed and plaster of Paris jacket was applied after 4 – 6 months which was replaced by an orthosis after about 1 – 2 months which was worn till the union (arthrodesis) was achieved.

Statistical Analysis

All data was recorded and analyzed using SPSS version 20. Qualitative data was presented in form of frequency (%). The quantitative data (age and curvature) is presented in the form of mean \pm S.D. The significance of procedure was compared in terms of curvature using Wilcoxon Rank test (due to small sample size). P-value \leq 0.05 was considered as significant.

Table 1: Comparison of Kyphosis and Scoliosis correction before and after surgery.

| | Kyphosis Cobb Angle | | Scoliosis Cobb Angle | |
|----------------|---------------------|--------|----------------------|-------|
| | Mean | SD | Mean | SD |
| Before surgery | 96.67 | 24.664 | 77.25 | 5.315 |
| After surgery | 58.33 | 17.559 | 45.00 | 5.354 |
| p-value | 0.000 (< 0.0001) | | 0.000 (< 0.0001) | |

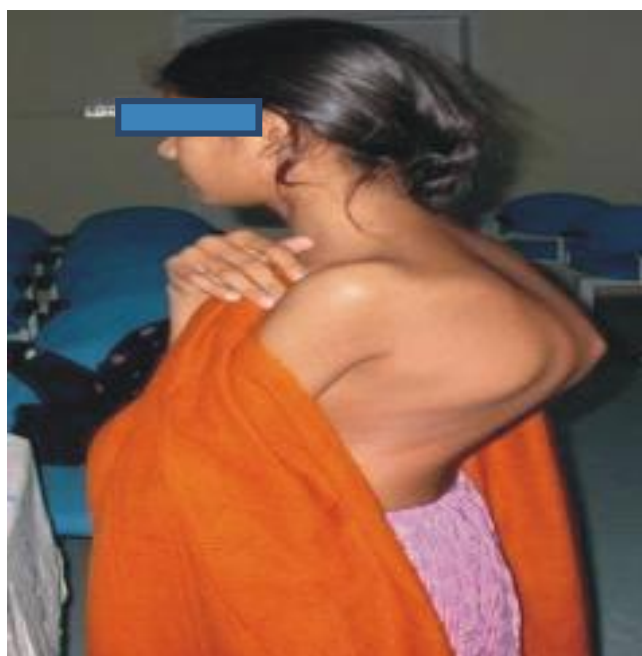
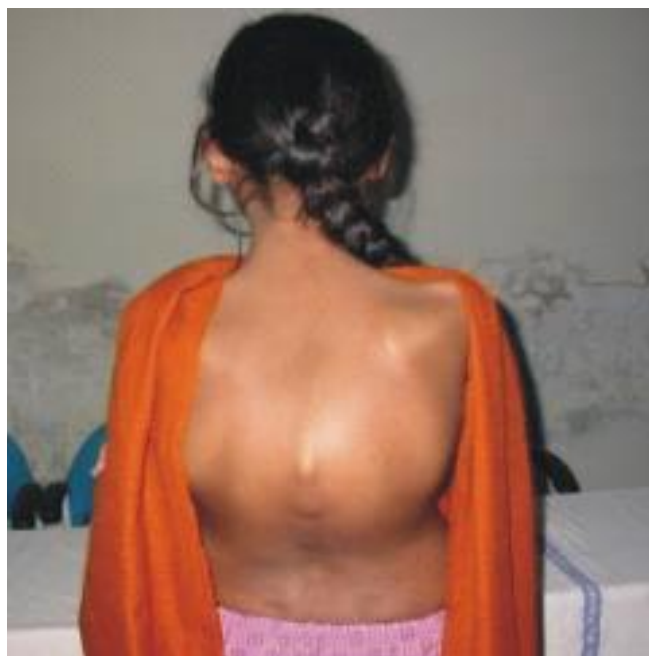
Fig. 1&2: Back and side view showing kyphotic deformity.

Results

There were 03(42.9%) males and 04 (57.1%) female between 8 to 17 years of age (Mean15.14 ± 3.23 SD). Amongst these 07 patients, 03(42.85%) presented with kyphosis and 04 (57.14%) presented with scoliosis. The magnitude of the scoliosis curve was in the range of 125° to 60°. The mean curvature of scoliosis was 77.25 ± 5.3 before treatment improved to 45 ± 5.35 (41.75%) after surgery with significant improvement (p < 0.0001). The mean curvature in kyphosis was 96.67 ± 24.66 which reduced to 58.33 ± 17.56 (39.66%), p < 0.0001 (Table 1).

One female patient developed paraplegia which recovered completely after decreasing traction. One had CSF discharge from a cranial pin which recovered after pin removal. There was no serious pin tract infection in this series.

Discussion

The correction of severe spinal deformities is difficult. Severe rigid spinal curve can be corrected with staged surgeries. Halo-pelvic traction can be helpful in the correction of these severe spinal deformities. It provides better outcomes in problematic fixed spinal deformities. Pins insertion and infection required expertise and good care.^{9,10} The majority of problems are related to the pin sites and pin should be cleaned with antibacterial solution daily or as per needed on observation. In present study there was no major pin tract infection.

The age of the patients at the time of treatment ranged from 8 to 17 years (Mean 15.14 ± 3.23 SD). One female patient developed paraplegia who recovered incompletely after decreasing traction leaving six patients who completed their treatment. The average time in halo-pelvic apparatus was 26 weeks with

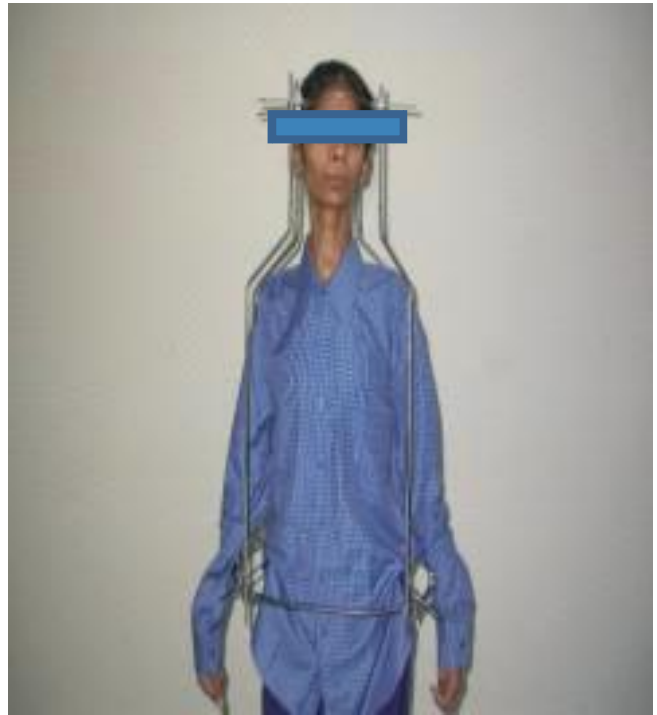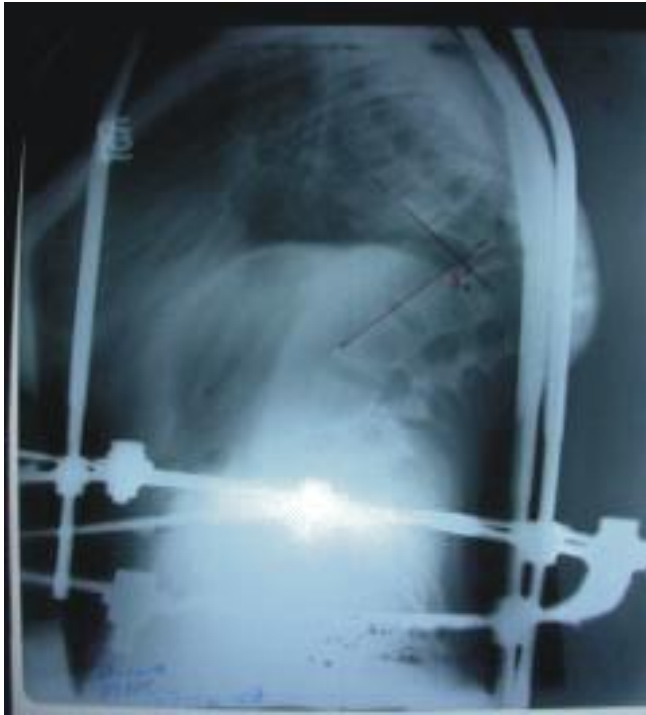


Fig. 3&4: X-ray Lumbosacral Spine (lateral view) showing Kyphus angle 100° and patient with Halopelvic traction.

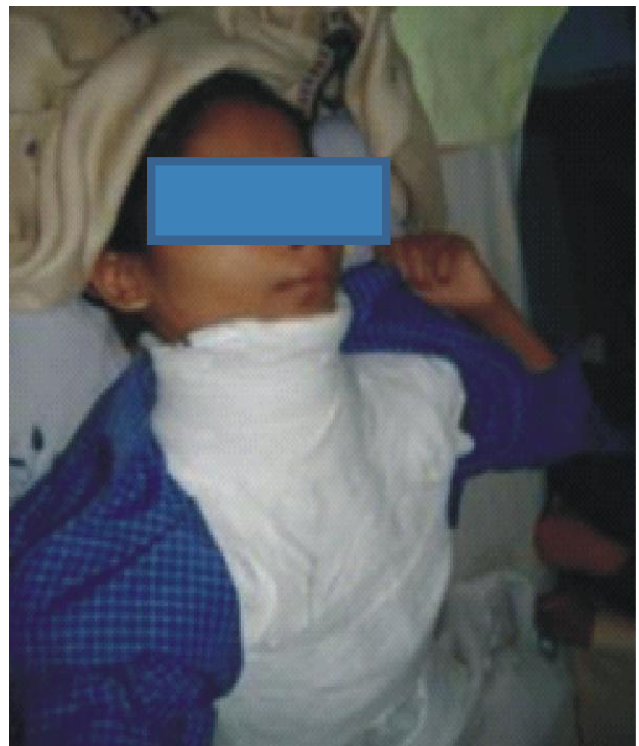
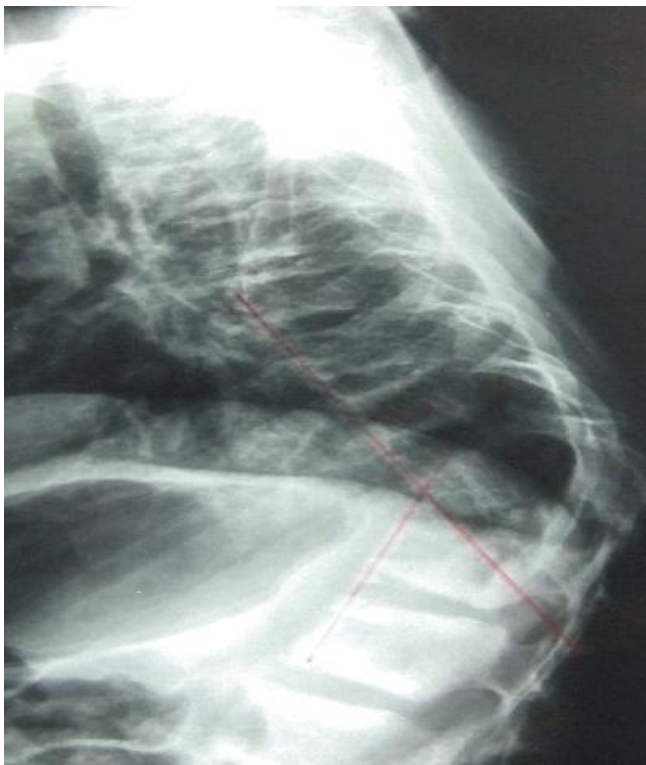
Fig. 5&6: X-ray Lumbosacral Spine (lateral view) showing Kyphus angle correction and patient with Plaster Jacket.



Fig. 7&8: Patient wearing Orthosis and after removing of orthosis.

average follow up of 24 weeks. The follow up was recorded from the date of removal of halo-pelvic apparatus.

In present study 6 patients had the deformity in the thoracolumbar spine and 01 had in cervicodorsal spine. The average number of diseased / destroyed vertebrae was 2. The D10 vertebra was most commonly involved and the most common site of kyphosis was dorsal spine. The severity of deformity was measured by Cobb method. Mean scoliosis was 77.25 ± 5.31 which improved to mean 41.75%. The mean kyphosis Cobb angle was 96.67 ± 24.66 (Range $60^\circ - 125^\circ$) which corrected to mean 39.66%.

O'Brien et al reported a case of paralytic scoliosis with 120 degree thoracolumbar curve corrected to 61 degrees (50.88%) with Halo-pelvic traction.¹⁰ In present study Cobb angle was corrected with mean of 39.66% for kyphosis and 41.74% for scoliosis. Kalamchi et al reported 36 patients with paralytic scoliosis secondary to poliomyelitis with average age of 14.6 years treated by halopelvic traction achieving 46% correction.¹¹ Yamin et al, treated 21 patients with average Cobb angle of 62° (range 40° to 89°) after first-

stage release and traction surgical procedures, the average correction achieved was 44.2% (range 23.9 to 63.9%) which improved to 65.2% (range 39.8% to 79.5%) in second stage instrumentation.¹²

Treatment outcome is influenced by the severity of deformity, flexibility of spine, age of the patient and type of deformity. Spinal cord has less tolerance to traction that's why paraplegia is not uncommon with other complications like pin loosening, pin infection, cranial nerve involvement etc. But with slow distraction a good correction may be achieved. The experience in this study with halo-pelvic traction method can be used in the treatment of severe and rigid deformities with magnitude of curve more than 70° and flexibility less than 10° that require staged surgery. The application of posterior instrumentation after correction of spine deformities with halopelvic traction is superior to our method but these gadgets are expensive, long learning curve for surgeons and have their own complications. The halo-pelvic distraction followed by arthrodesis of spine without instrumentation can be used in low socio-economic group due to low cost and good results.

Conclusion

Slow distraction by Halopelvic device is good and relatively cheaper procedure which can be used for correction of severe spinal deformities especially in our set up having poor socioeconomic status.

References

1. Cassidy RC, Calhoun JH. Kyphosis. MedScape. Retrieved May 2014.
2. Smith JT, Gollogly S, Dunn HK. Simultaneous anterior posterior approach through a costotransversectomy for the treatment of congenital kyphosis and acquired kyphoscoliotic deformities. *The Journal of Bone & Joint Surgery*, 2005; 87 (10): 2281-9.
3. Orenstein WA, Wharton M, Bart K, Hinman A. Immunization. *Goldman's Cecil Medicine 24th ed* Philadelphia, Pa: Elsevier Saunders. 2011.
4. Orthospine. Scoliosis / Kyphosis. Retrieved on May 2014.
5. McMaster MJ, Singh H. The surgical management of congenital kyphosis and kyphoscoliosis. *Spine*, 2001; 26 (19): 2146-54.
6. Bradford D. S, Moe J. H and Winter R. B: In the Spine, edited by R. H. Rothman and F. A. Sirneone. Vol. 1. Chap. 6. Philadelphia. W. B. Saunders, 1975.
7. Dewald R. L and Ray R. D: Skeletal Traction for Treatment of Severe Scoliosis. The University of Illinois Halo-Hoop Apparatus. *J. Bone and Joint Surg.* March, 1970; 52 A: 233-238.
8. Perry J A, Quelin and Nickel, VL. Total Cervical-Spine Fusion for Neck Paralysis. *J. Bone and Joint Surg.* 1959; 41-A: 37-59.
9. Moe JH. Complications of scoliosis treatment; *Clin. Orthop.* 1967; 53: 21-30.
10. O'Brein JP, Yau ACMC, Smith TK, Hodgson AR. Halo-pelvic traction, A Preliminary Report on a Method of External Skeletal Fixation for Correction Deformities and Maintaining Fixation of Spine: *J. of Bone and Joint Surg.* May, 1971; 53B: 217-229.
11. Kalamchi A, Yau A, O'Brien JP, Hodgson AR. Halo-pelvic distraction apparatus. An analysis of one hundred and fifty consecutive patients. *The Journal of Bone & Joint Surgery.* 1976; 58 (8): 1119-25.
12. Yamin S, Li L, Xing W, Tianjun G, Yupeng Z. Staged surgical treatment for severe and rigid scoliosis. *Journal of Orthopaedic Surgery and Research*, 2008; 3 (1): 26.