

Analytical study of Ossicular Chain in Middle Ear Cholesteatoma

SALMAN A A.,¹ AZHAR H.,² MUHAMMAD E K.,³ AND MUHAMMAD M.⁴

Address for Correspondence: Department of E.N.T and Head and Neck Surgery and Department of Pathology, King Edward Medical University, Lahore.

Objective: The objective of the study was to detect and analyse frequency of occurrence of different types of ossicular chain defects in chronic suppurative otitis media with cholesteatoma on mastoid exploration and to identify the ossicle most commonly eroded by cholesteatoma.

Study Design: Analytical study

Materials and Methods: A total of 75 cases of chronic suppurative otitis media with cholesteatoma with different age groups were admitted at E.N.T. Unit-1, Mayo Hospital, Lahore from July 2002 to July 2005. Each patient had essentially the work up according to the specific Performa.

Results: Ninety seven percent (97%) cases showed the ossicular erosion while 3% cases showed intact ossicle i.e., all ossicle were intact. The Long process of incus was the commonest portion involved and then stapes supra-structure. Cholesteatoma was more common in the males (52%) than in the females (48%). Majority of patients i.e. 52% were in the age group of 16-30 years. It is also revealed that majority of patients belonged to poor communities living in rural or slum areas of the cities.

Conclusion: The most common presenting feature of chronic suppurative otitis media with cholesteatoma was ear discharge. Most of the cases showed the ossicular erosion and incus was most commonly involved. Cholesteatoma is more common in males than in females. Cholesteatoma is more common in low socioeconomic groups.

Key words: Cholesteatoma, Ossicles, Chronic suppurative otitis media with Osteitis.

Introduction

Cholesteatoma is an abnormal collection of viable and desquamated squamous epithelium in the middle ear or mastoid air spaces¹. Alternatively cholesteatoma may be taken as a three dimensional epidermal and connective tissue structure, usually in the form of a sac and frequently conforming to the architecture of the various spaces of middle ear, attic and mastoid. This structure has the capacity for progressive and independent growth at the expense of underlying bone and has a tendency to recur after removal². Although cholesteatomas are more commonly found in the middle ear and mastoid, the disease can occur in the external ear canal and very rarely it may present as a lump on the side of a patient's head eroding the squamous temporal bone with intracranial extension.³

Chronic suppurative otitis media is a common ailment seen in the specialty of ear, nose and throat. Unsafe type of this disease previously known as attic-antral type usually presents with marginal perforation having cholesteatoma which is the hallmark of this affection and also considered as the complication producing element.^{4,5}

Erosion of bone is an established pathological characteristic of cholesteatoma.^{6,7} Severe bone destruction in a cholesteatoma is one of the characteristic clinical features.⁸ The mechanism of this bone destruction has been widely debated. First ever interpretation in this regard was that destruction of bone occurs due to pressure exerted by the expansion of cholesteatoma.⁹⁻¹¹ Some other investigators suggested that a chemical process is responsible for lytic

effect on the bone. According to data obtained by Raman through spectroscopy, the inorganic substances present in normal bone of living body seems to dissolve in otorrhea fluid, which has been rendered acidic due to fatty acids. This process is called demineralization. Interlukin-I has been found in cholesteatoma by immunoperoxidase and immunofluorescence techniques. Interlukin-I can directly activate osteoclasts^{12,13} by producing osteoclast activating factor.¹⁴ It also promotes migration of inflammatory cells and stimulates fibroblasts to produce prostaglandins and collagenase. Whatever may be the mechanism of bone destruction, the fact is that cholesteatoma spread in and across middle ear cleft with a potential to lead to both intracranial and extracranial complications, ranging from severe ear pain, foul smelling ear discharge, deafness to well known complications like facial paralysis, meningitis, sigmoid sinus thrombosis, epidural abscess and brain abscess.¹⁵

Erosion of ossicles occurs in three stages, pitting, pitting and cavitation.¹⁶ Basically there are four major ossicular defect that may result from erosion by cholesteatoma giving rise to deafness. The most common is involvement of only the long process of incus¹⁵ with intact malleus and stapes. The second most common defect is erosion of the supra structure of the stapes as well as loss of incus. Third, the cholesteatoma growing into the middle ear involves the malleus handle which may necessitate its removal along with the incus, however the stapes remains intact. Finally there may be loss of all ossicles except the stapedial foot plate. Erosion of the long process of the incus by chole-

teatoma is the most frequently encountered defect of the ossicular chain. The reason is due to its delicate structure and location rather than its tenuous blood supply.¹⁸

Aims and Objective

The objective of the study was to detect and analyse frequency of occurrence of different types of ossicular chain defects in chronic suppurative otitis media with cholesteatoma on mastoid exploration and to identify the ossicle most commonly eroded by cholesteatoma.

Materials and Methods

A total of 75 cases of chronic suppurative otitis media with cholesteatoma with different age groups were admitted at E.N.T. Unit-1, Mayo Hospital, Lahore between July 2002 to July 2005. Each patient had essentially the work up according to the specific Performa.

It includes history including history of present illness, past history, family history and socio-economic status history, examination and investigations of ear, nose and throat including otoscopic and microscopic examination of ear, culture and sensitivity of the discharge from the ear.

The most important method in the diagnosis and management of the disease was the use of operating microscope, which gave a great deal of information as to nature and extent of the disease. An important aid was made by radio-

The cases were operated by both techniques i.e Radical mastoidectomy and Modified radical mastoidectomy and ossicular status was assessed.

The data comprised of 75 patients with certain descriptions about various parameters e.g. duration of disease, presenting features, ossicular status in cholesteatoma, complications, pre-operative pathological findings, radiographic findings etc. The investigation was based upon descriptive statistics involving frequency distribution graphs and calculation of percentages in order to have easier understanding about the relative occurrence of those parameters.

Results

Ninety seven percent (97%) cases showed the ossicular erosion while 3% cases showed intact ossicles i.e., all ossicles. The Long process of incus was the commonest portion involved and then stapes supra-structure.

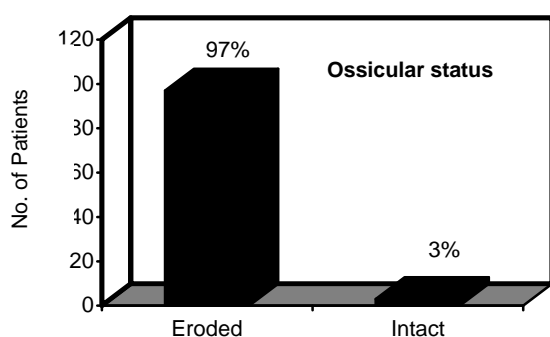
Discussion

Chronic suppurative otitis media is a persistent disease with insidious onset and can cause dangerous life threatening complications if left untreated or treated inadequately and are frequent in conjunction with cholesteatoma.

All the seventy-five cases of chronic suppurative otitis media presented with the most common complaint of ear discharge (100%). During surgery, cholesteatoma alone and

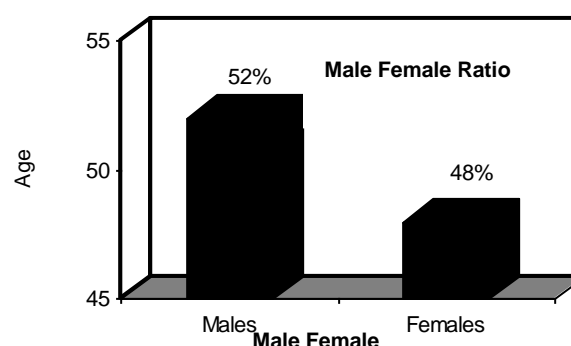
cholesteatoma with granulations appeared to be the commonest finding.

No. of Patients	Males	Females	Examination under microscope findings	Cases showing ossicular erosion	Cases showing intact ossicles
75	52%	48%	Attic and posterior perforation	97%	3%



Cholesteatoma was more common in males (52%) than in females (48%).

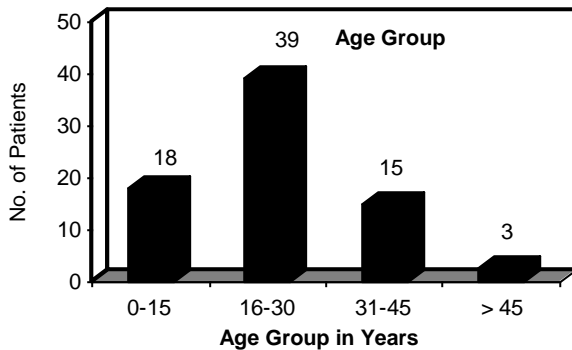
graphy, the X-ray mastoid which gave information as to the degree of pneumatization, extent of the disease and the general anatomical outline of temporal bone. Computerized tomography scan in cases of intracranial complications was done to locate the site and extent of the lesion in the brain. The material for histopathology was obtained during the operative procedure to confirm the diagnosis and disease pathology.



Majority of patients i.e. 39 cases (52%) were in the age group of 16-30 years of their ages, next 18 cases (24%) in the age group of 0-15 years and 15 cases (20%) in the age group of 31-45 years while only 03 cases (04%) patients were above 45 years of age. In the present study young adults of age 16-30 years were found more indisposed than old ones.

In this study 97% cases showed the ossicular erosion while 3% cases showed intact ossicle i.e all ossicle. The Long process of incus was the commonest portion involved and then stapes supra-structure.

Cholesteatoma was more common in males (52%) than in females (48%). Our finding regarding the male female ratio correlates with that of another study showing that the majority of patients of chronic suppurative otitis media with cholesteatoma were males.¹⁹



It is revealed that majority of patients belonged to poor communities living in rural or slum areas of the cities where infections were more common

Majority of patients i.e. 39 (52%) were in the age group of 16-30 years of their ages, next 18 (24%) in the age group of 0-15 years and 15 (20%) in the age group of 31-45 years while only 03 (04%) patients were above 45 years of age. In the present study young adults of age 16-30 years were found more indisposed than old ones. Our findings contradicted with those of Cruz et al (1990) who showed that peak incidence was in 10-15 years age group.²⁰ Our finding regarding the age of the patients correlates with another study which showed almost same incidence of age relation. That study stated that the peak incidence of the disease was in the age group between 21 yrs to 30 yrs.^{21,22}

It is revealed that majority of patients belonged to poor communities living in rural or slum areas of the cities where infections were more common due to unbalance diet and poor hygiene.

Conclusion

Chronic suppurative otitis media is a common ailment in the speciality of ear, nose and throat. Unsafe type of this disease known as attic-antral type of chronic suppurative otitis media usually presents with marginal perforation having cholesteatoma which is the hallmark of this affection and also considered as the complication producing element. Cholesteatoma, a non neoplastic destructive lesion, is the commonest finding in operated cases of chronic suppurative otitis media. The most common presenting features of chronic suppurative otitis media with cholesteatoma was ear discharge in all patients (100%). 97% cases showed the ossicular erosion and 3% cases showed all the ossicles intact. It was found that incus was most commonly involved and then stapes supra-structure. Cholesteatoma is more common in

males than in females i.e 52% males and 48% females. Cholesteatoma is more common in young adults between 16 to 30 years of the age than in old ones. And it was also observed that cholesteatoma is more common in low socio-economic groups and slum areas of the cities where infections are more common due to unbalance diet and poor hygiene.

References

1. McKenney KX. Cholesteatoma: recognition and management. *Am Fam Physician*. 1991.
2. Harold Ludman, Diseases of ear, 5th Edition, chap. 28, chronic suppurative otitis Media-Cholesteatoma, Robin Youngs, Page no. 386.
3. Griffith H. Ran A, Hayes M. cholesteatoma, An unusual presentation. *J Laryngol Otol* 2000. 114: 957-58.
4. Hameed A, Ahmad M, Amjad M, Shakeel A, Rizvi A: Ossicular defects in cholesteatomatous chronic suppurative otitis media. *Pak postgraduate Med J*.1998; 9; 35-7.
5. O'Leary S, Veldman JE. Revision surgery for chronic otitis media recurrent-residual disease and hearing. *J Laryngol Otol* 2002; 116 (12) 996-1000.
6. Scott Brown's otorhinolaryngology and head and neck surgery. 7th Edition, page no. 3399.
7. Harold Ludman, Diseases of ear, 6th Edition, page 391.
8. Yutaka Kaneko. MD, R Yuasa, MD, Ikuo I, MD, Yuki-ko Iino MD, Hibbichi Shinkawa MD, Masaaki Rukugo, MD. Sachiko Tomioka, MD, Yoshihiro Shibahara, MD. Bone destruction due to rupture of a cholesteatoma sac: A pathogenesis of bone destruction in aural cholesteatoma: the Laryngoscope.
9. Ruedi L. Cholesteatoma of attic. *J Laryngol Otol* 1958; 72: 593-609.
10. Ballenger's Otorhinolaryngology and head and neck surgery, 16th Edition, chapter 10, Chronic otitis Media, topic: Bone Erosion p.: 265.
11. Ballenger's Otorhinolaryngology and head and neck surgery, 16th Edition, chapter 10, Chronic otitis Media, topic: Bone Erosion p.: 265.
12. Orisek BS, Chole RA. Pressure exerted by experimental cholesteatomas. *Arch otolaryngol head neck surg* 1987; 113; 386-91.
13. Harold Ludman, Diseases of the ear; chap 28; Chronic suppurative otitis media- Cholesteatoma. ; p. 391.
14. Kurihara A, Toshima M, Yuasa R, Takasaka T, Bone destruction mechanism in chronic otitis media with cholesteatoma in culture of bone resorbing activity attributable to interleukin-I alpha. *Annals of otology, Rhinology and laryngology* 1991; 100: 989-98.
15. Glasscock Shambaugh's Surgery of the ear, 5th Edition, Chapter 21, Pathology and clinical course of inflammatory diseases of the middle ear.
16. Wong J, Stoney P, Hawke M., Ossicular erosion by cholesteatoma: investigation by scanning electron microscopy utilizing a new preparation technique. *J Oto-*

- laryngol. 1991.
17. Tos M, Pathology of the ossicular chain in various chronic middle ear diseases. *J Laryngol Otol* 1979, Aug; 93 (8): 769-80.
 18. Scott-Brown's otorhinolaryngology and head and neck surgery. 7th Edition, chap. 237 c, chronic otitis media, p: 3399.
 19. Muhammad Amjad, Nasim Abbas: Incidence of cholesteatoma in various age, sex and socioeconomic groups; *Ann King Edward Medical coll* : Oct. – Dec. 1998; 4 (4): 65-66.
 20. Cruz OL, Takeuti M, Caldas-Neto S, Miniti A. Clinical and surgical aspects of cholesteatoma in children. *Ear-Nose-Throat-J* 1990; 69: 530-5.
 21. Mushtaque Ali Memon, Salman Matiullah, Zeba Ahmed and Muhammad Saleem Marfani: Frequency of un-safe chronic suppurative otitis media in patients with discharging ear *J Liaqat Uni Med Health Sci* May-August 2008; 7 (2); 102-5.
 22. Alam J, Udaipurwala IH, Jailisi M: Surgical management of CSOM; experience at civil Hospital Karachi *Pak J Otolaryngol* ; 2000; 16; 36-9.