

# Crab Louse Infestation of Eyelashes

A HYE

Department of Ophthalmology, Allama Iqbal Medical College/Jinnah Hospital, Lahore  
Correspondence to Dr. Abdul Hye, Assistant Professor

**Purpose:** To present clinical features and management of ten patients of crab louse infestation of eyelashes  
**Methods:** Present study includes ten cases of crab louse infestation of eyelashes seen during last few years in eye OPD of Services Hospital & Jinnah Hospital Lahore. Patients visiting eye out-patients department who were reported to have crab louse infestation of eyelashes were examined in detail including systemic examination. Infested parts of the body were photographed as well. The adult patients were asked about similar problem in their sexual partners and the parents of children were inquired similarly. All patients were treated with adequate washing of eyelashes and other involved parts with soap and water and application of any ophthalmic preparation having petroleum base e.g. Polyfax eye ointment in the conjunctival sac and eyelashes and anti-lice dermal preparation e.g. Lotrix (Permethrin) skin preparation to other parts. All patients were followed for a period of three months performing examination of eyelashes with slitlamp and systemic examination every two weeks.  
**Results:** Seven out of ten patients were adults (70%), five males and two females, and remaining three patients were children (30%). Forty percent of patients (4/10 patients) had related systemic lesions, including blue gray macules (Maculae caeruleae) and the bullous lesions. In addition to systemic dermatological manifestations, ocular symptoms included deposits in the roots of eyelashes, irritation or feeling of some thing moving in lid margins, mild lacrimation and redness. Ocular examination revealed multiple lice anchoring themselves in the roots of eyelashes sucking blood, along with hundreds of nits cemented with eyelashes. There was a mild conjunctival congestion. Removal of lice resulted in formation of small ulcers of margin of lid. Adequate washing with soap and water, followed by application of Polyfax eye ointment for two to three weeks, resulted in complete cure of the palpebral disease.  
**Conclusion:** This study emphasizes the significance of an infrequently seen clinical condition of crab louse infestation of eyelashes, not only as a venereal disease expecting much higher number of infections but also as an important cause of refractory cases of chronic irritation of eyes with blepharitis. Careful examination of eyelids with slitlamp microscope may establish the diagnosis. All the sexual partners should be treated simultaneously. Other parts of the body having less dense population of hair should be examined and adequate measures should be taken for the management, including application of anti-lice dermal ointment e.g. Lotrix (Permethrin) skin ointment.

**Key words:** Crab louse, infestation, eye lashes

Crab louse infestation of eyelashes is very infrequently seen in clinical ophthalmic practice, although the actual number of infections is considered much higher<sup>1</sup>. Present study includes ten cases of crab louse infestation of eyelashes seen during last few years in eye OPD of Services Hospital & Jinnah Hospital Lahore.

## **Purpose:**

To present clinical features and management of ten patients of crab louse infestation of eyelashes

## **Methods:**

Patients visiting eye out-patients department who were reported to have crab louse infestation of eyelashes were examined in detail including systemic examination. Infested parts of the body were photographed as well. The adult patients were asked about similar problem in their sexual partners and the parents of children were inquired similarly. All patients were treated with adequate washing of eyelashes and other involved parts with soap and water and application of any ophthalmic preparation having petroleum base e.g. Polyfax<sup>®</sup> eye ointment in the conjunctival sac and eyelashes and anti-lice dermal preparation e.g. Lotrix (Permethrin) skin preparation to other parts.

All patients were followed for a period of three months performing examination of eyelashes with slitlamp and systemic examination every two weeks.

## **Case 1:**

A young male, 24 years of age, presenting as irritation in both eyelid margins of both sides with lacrimation and grayish deposits in the roots of eyelashes described as dandruff by the patient.

Examination with slitlamp revealed the presence of dozens of nits cemented to eyelashes, each eyelash having one or two nits. In between the roots of eyelashes near the margin of eyelid, a thin capillary like streak of blood was visible in the center of body of an insect, the crab louse. These were present in large number, in both lids, in both eyes and had three distinct pairs of legs by which these were holding the adjacent eyelashes firmly. Just near the tail end of each louse, rust colored or dark colored specks of blood, being extruded out of the body of louse, were visible. Rather it was presence of these rust colored specks of blood, which guided me towards the presence of an insect within the roots of eyelashes. Conjunctiva showed mild congestion of non-specific nature associated without any other positive finding.

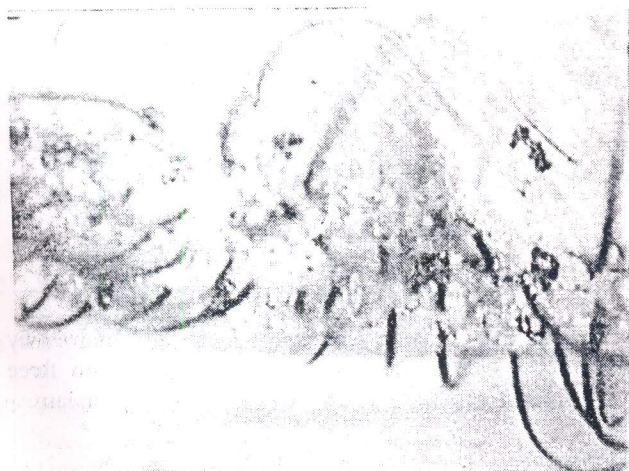The patient not only had a poor socio-economic status but also a poor personal hygiene. No other part of

body was found to be involved. He denied similar infestation of any other sexual partner. He was advised to see the author next day for photograph and video recording and management. Next day he reported after taking a good bath including adequate washing of the eyelashes of both eyes. On examination only one louse could be found in the eyelashes of one eye only and with few eggs still firmly attached to the eyelashes. These were removed manually under magnification resulting in cure of the condition. No significant lesion was found in the margin of eyelashes, which could indicate the sites of previous attachment of the lice

**Case 2:**

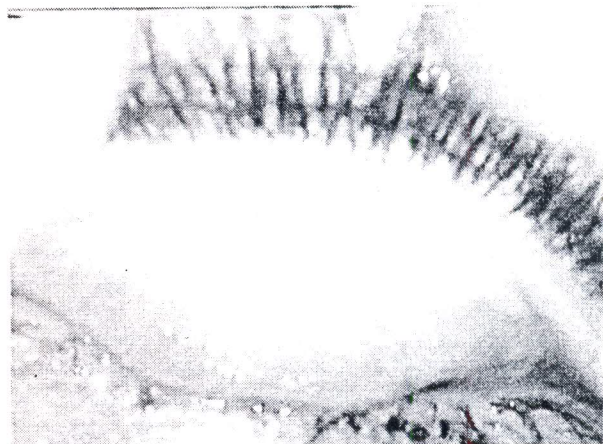Second case was a young lady of about 23 years, appearing to have good personal hygiene, was working at beauty parlor and hair cutting shop. She presented with a feeling of presence of some moving thing in the eyes, irritation and mild watering both eyes, in addition to presence of brownish deposits in the roots of eyelashes, described as dandruff. On examination of her eyelids, the lashes were flooded with eggs of lice and there were many lice anchoring themselves at the marginal strip, (Fig 1) having similar whitish gray squat body, central fresh blood streak and specks of rust colored blood, being extruded out of their bodies. These lice were holding the adjacent lashes with their claws shaped three pairs of legs (Fig 2). A mild conjunctival congestion was present, which was more near the margin. (Fig 3)

She was advised to wash her eyelashes with soap and water and to apply ample amount of Polyfax eye ointment over the roots of lashes and within the eye in order to interfere with respiratory function of the lice, because other specific eye ointments against the lice e.g. Physostigmine, are not available in Pakistan.



**UPPER LID EYELASHES  
HUNDREDS OF NITS & MANY LICE ARE VISIBLE**

Fig.1: Upper lid eyelashes hundred of nits and many lice are visible



**UPPER LID CONGESTION OF CONJUNCTIVA**

Fig.2: Upper lid congestion of conjunctive

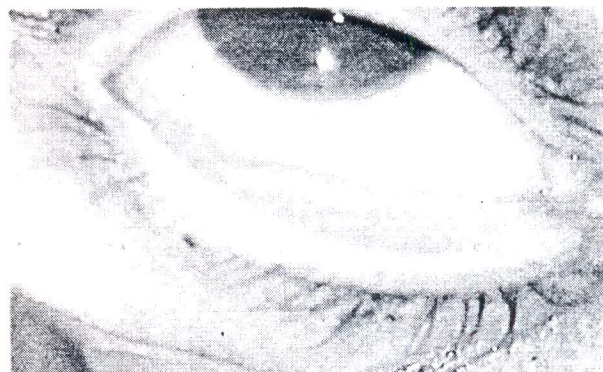

Fig.3: Lower lid conjunctival congestion


**Third and fourth cases:** Third and fourth case seen, were two children, a brother and a sister, ages 5 and 3 years, of middle socio-economic status and having good hygiene. Both children have involvement of both eyes and the presenting features were itching, redness, watering, and whitish deposits in the eyelashes. Their mother noticed the presence of lice in the eyelashes few weeks after they had a pet cat. Despite adequate washing with soap and water there was no improvement during the last two months. Examination of the eyelids revealed the presence of many lice and nits similar to those described earlier.

No other part of the body was found to be involved. The mother denies similar lice infestation of either of the parents.

**Fifth case:** A young male, 19 years of age, a student, presented as presence of lice on the trunk, pubis, and legs for the last three months. A day before he noticed presence of lice and nits in the eyelashes when he removed one louse with his hand so confirming its presence in the eyelashes. There was a slight irritation in lid margins along with redness of lower part of right eye. On examination, there was a moderate congestion of lower palpebral conjunctiva and adjacent bulbar conjunctiva. (Fig 4) The upper lid was heavily infested with lice, the roots of the


eyelashes being colonized by the lice. The lower eyelid had only four lice which were hardly visible without the help of microscope. Systemic examination revealed louse infestation of trunk (Fig 5), pubic hair (Fig 6), and legs. The maculae cerulae (Fig 5) and the bullous lesions (Fig: 7). which are considered as skin manifestations of crab louse, were also found.

**Last five patients** included four males and one female patient. Two males and one female had systemic manifestations as well, along with similar ocular manifestations.



**PUBIC HAIR INVOLVEMENT BY LOUSE NITS ARE ALSO VISIBLE CEMENTED WITH NEARBY PUBIC HAIR**

Fig.5: Pubic hair involvement by louse nits are also visible cemented with nearby pubic hair



**SKIN RASH DESCRIBED TO BE CAUSED BY CRAB LICE OVER ABDOMINAL WALL**

Fig.4: Maculae cerulae described to be caused by crab lice over abdominal wall

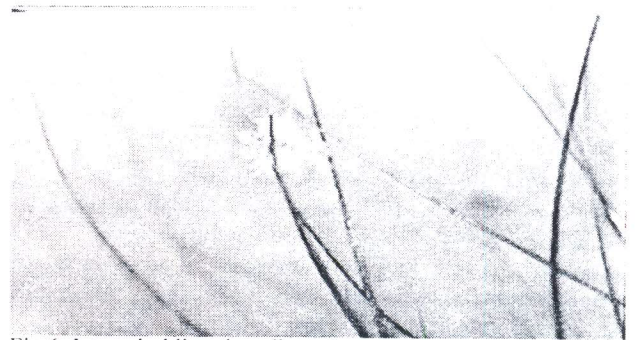

Fig.6: Louse holding the adjacent eye lashes

**Results:**

Seven out of ten patients were adults (70%), five males and two females, and remaining three patients were children (30%). Forty percent of patients (4/10 patients) had related systemic lesions, including blue gray macules (Maculae caeruleae) and the bullous lesions. (Table 1)

Table 1: of details of patients

Patients	Age(years)	Sex	Area of systemic involvement	Special lesions Seen
1	26	Male	Nil	Nil
2	23	Female	Nil	Nil
3	5	Male	Nil	Nil
4	3	Female	Nil	Nil
5	19	Male	Pubic hair, Anterior Abdomen, Thighs,	Maculae caeruleae, Bullous lesions.
6	29	Male	Pubic hair, Abdominal hair, Inside of thighs	Maculae caeruleae, Bullous lesions.
7	27	Female	Pubic hair, Abdominal hair, Inside of thighs	Maculae caeruleae, Bullous lesions.
8	9	Male	Nil	Nil
9	26	Male	Pubic hair, Abdominal hair, Inside of thighs.	Maculae caeruleae, Bullous lesions.
10	31	Male	Nil	Nil

In addition to systemic dermatological manifestations, ocular symptoms included deposits in the roots of eyelashes, irritation or feeling of some thing moving in lid margins, mild lacrimation and redness. Ocular examination revealed multiple lice anchoring themselves in the roots of eyelashes sucking blood, along with hundreds of nits cemented with eyelashes. There was a mild conjunctival congestion. Removal of lice resulted in formation of small ulcers of margin of lid.

Adequate washing with soap and water, followed by application of Polyfax eye ointment for two to three weeks, resulted in complete cure of the palpebral disease.

**Discussion:**

Lice are members of order PHTHIRAPTERA. These are wingless dorso-ventrally flattened insects. Man is parasitized by two species of suborder Anoplura; Pediculus Humanus and Phthirus Pubis. Anoplura are vessel

feeders<sup>2,3</sup> piercing the small blood vessel sucks the blood by a group of stylets, which are present within the head of insect.

*Phthirus pubis* or Crab louse is specific parasite of human<sup>7</sup>. It is quite distinct from head louse, its body is squat and 2<sup>nd</sup> and 3<sup>rd</sup> pairs of legs carry heavy pincer-like claws to grip adjacent hair close to skin surface. Its eggs are light brown color and are cemented to the hair. It is transmitted by close physical contact, usually sexual in young adults, while in children it is usually acquired from infected parents<sup>5</sup> and may colonize in scalp as well<sup>6</sup>. Many adult patients suffering from crab lice infestation were found to be suffering from other sexually transmitted disease as well<sup>7</sup>.

Itching of the involved area like pubic hair, axilla, eyebrows, and eyelashes is the main symptom. It is mainly in the evening and at the night. In contrast to the head louse, these are slow moving insects, which move by holding the hair one after the other with two pairs of claw legs. These insects are not usually found in more dense hair like those of scalp. Blue gray macules (*Maculae caeruleae*)<sup>8</sup> and the bullous lesion<sup>9</sup>.

Attributed to crab louse have been reported. Other clinical features of eyelid infestation are the presence of large number of lice eggs attached firmly to the eyelashes appearing as deposits and presence of small specks of rust colored blood in between the eyelashes. The presence of mild degree of blephritis has also been observed in all these five cases, along with mild conjunctival congestion.

Any ointment might be expected to interfere with respiratory function of the louse and the use of thick application of any petroleum jelly twice a day for 2-3 weeks has been recommended<sup>10</sup>. Physostigmine eye ointment is very popular among the ophthalmologists. Ocular side effects of physostigmine, like pupil constriction, and paralysis of accommodation are the drawbacks.

Carbaryl and Malathion are good against the louse, but ocular preparations are not available, so it is preferred to use petroleum.

Other methods, which may be adopted, are as follows:

1. Mechanical removal of lice and nits with fine forceps<sup>11, 14</sup> or epilation of lashes with attached eggs may be uncomfortable to the patient.
2. Cryo-therapy has been used to destroy crab louse in the eyelashes<sup>12,15</sup>.
3. Use of Fluorescein in a concentration of 10-20 % is also said to be effective<sup>13,16</sup>.
4. Argon laser therapy has also been used to destroy the lice<sup>17</sup>.

Due to the non-availability of most of the above mentioned methods of treatment in Pakistan, it is recommended that patient should be asked to wash the eyelashes and the eyebrows with soap and water twice daily, followed by thick application of any of the eye

ointment containing petroleum, for 2-3 weeks. It will be an effective treatment. Lashes should be examined under slit lamp microscope for presence of nits or lice before the treatment is discontinued.

#### Conclusion:

This study emphasizes the significance of an infrequently seen clinical condition of crab louse infestation of eyelashes, not only as a venereal disease expecting much higher number of infections but also as an important cause of refractory cases of chronic irritation of eyes with blepharitis. Careful examination of eyelids with slitlamp microscope may establish the diagnosis. All the sexual partners should be treated simultaneously. Other parts of the body having less dense population of hair should be examined and adequate measures should be taken for the management, including application of anti-lice dermal ointment e.g. Lotrix (Permethrin) skin ointment.

#### References:

1. Rook / Wilkinson / Ebling Text Book of Dermatology, 6<sup>th</sup> edition (1998), vol.2, page 1443, Incidence and epidemiology of phthiriasis pubis.
2. Lavoipierre MMJ. Feeding mechanism of blood-sucking arthropods. *Nature* 1965; 208: 302-3.
3. Lavoipierre MMJ. Feeding mechanism of *Haematopinus susis* on the transilluminated mouse ear. *Exp Parasitol* 1967; 20: 303-11.
4. Frye FL, Furman DP. Phthiriasis in a dog. *J Am Vet Med Assoc*. 1968, 152: 1113.
5. Alexander JO'D *Phthirus pubis* infestation of the eyelashes. *JAMA* 1983; 250: 32.
6. Korting CW. phthiriasis palpebrarum-und ihre ersten historischen Erwahnungen. *Hautarzt* 1967; 18: 73-4.
7. Fisher I, Morton RS. Phthiriasis pubis infestation. *Br J Vener Dis* 1970; 46: 326-9.
8. Pavlovsky EN, Stein AK, *Maculae caeruleae* and *Phthirus pubis*. *Parasitology* 1924; 16: 145-9.
9. Safdi SA, Farrington I. Constitutional reactions and maculae caeruleae attending phthiriasis pubis. *Am. J. Med Sci* 1947; 214: 308-11.
10. Kern AB Bullous eruption due to Pediculosis Pubis. *Arch. Dermatol. Syphilol.* 1952; 65: 334-9.
11. Orkin M, Maibach HI. Treatment of today's pediculosis. In: Orkin M, Maibach HI, Eds. *Cutaneous Infestations and Insect Bites*. New York: Marcel Dekker 1985; 213-17.
12. Orkin M, Epstein E, Maibach HI, Treatment of today's scabies and pediculosis. *JAMA* 1976; 236: 1136-9.
13. Rasmussen JE. Pediculosis and the pediatrician. *Pediatr Dermatol* 1984; 2: 74-9.
14. Ronchese F. Treatment of Pediculosis ciliarum in an infant. *N Engl J Med* -1953; 249: 897-8.
15. Awan KJ. Cryo-therapy in phthiriasis palpebrarum. *Am. J Ophthalmology* 1977 83: 906-7.
16. Methew M D'Souza P, Mehta DK. A new treatment of phthiriasis palpebrarum. *Ann. Ophthalmol.* 1982; 14:439-41
17. Kanski J Clinical ophthalmology 5<sup>th</sup> Edition 2003; page 5 Phthiriasis palpebrarum.