

Unilateral High Division of Right Sciatic Nerve

M NASIM S KHALID H NABEEL

Department of Anatomy, Fatima Memorial Hospital, Lahore
Correspondence to Prof. Mamoona Nasim

A thorough knowledge of pelvis and lower extremity is of paramount importance in providing effective care to patients with lower extremity neuralgia. Neuroanatomy knowledge typically acquired in medical colleges at undergraduate level is limited and may not adequately equip the clinicians to effectively manage a patient with intractable pain of lower extremity especially if the nerves are not following a typical course. Sciatic nerve is the main nerve supplying most of the muscles and all of the joints of lower limb. It is a branch of Sacral plexus that leaves the pelvis usually below the piriformis muscle and after supplying the hamstring compartment divide at the level of apex of popliteal fossa into its two terminal divisions namely; Tibial And Common peroneal nerves. Sometimes Sciatic nerve while in the pelvis divides into its terminal branches that leave the pelvis in a number of ways in relation to piriformis muscle. This high division is responsible for ischalgia, wrongly placed intra-muscular injections and piriformis syndrome. This study is carried out in various medical colleges of Lahore including FMH college of Medicine and Dentistry to update the statistical data provided to the therapist and clinicians managing patients of sciatica, ischalgia or piriformis syndrome.

Key words: Sciatic nerve, piriformis muscle, high division

The sciatic nerve is the largest branch of sacral plexus with a root value of L 4,5, S 1,2,3. The nerve usually divides into its two terminal branches tibial and common peroneal at the apex of popliteal fossa^{1,2}. However, in approximately 12% cases the sciatic nerves bifurcates in the pelvis³. The tibial and common peroneal nerves separated as they left the pelvis. In approximately 85% cases the sciatic nerve passes anterior to the lower belly of piriformis muscle, in 10 % cases the divided nerve passes through and below the piriformis muscle.

In 1944 Boileau G. reported variations in the course of sciatic nerve. He found in 87 % of cases the sciatic nerve followed the usual below the piriformis course, in 12.2 % cases high division of sciatic nerve was observed with Common peroneal division passing through the piriformis and in 0.5 % cases above the piriformis through the supra-piriformis foramen³.

In an another study carried out by Charamza.J.⁴ three different courses adopted by Common peroneal division of Sciatic nerve dividing in the pelvis were observed The common peroneal and tibial passing through infra-piriformis foramen. The common peroneal passing through the piriformis, Common peroneal nerve passing above the piriformis,

Observations: Seventy-eight cadavers dissected in various medical colleges of Lahore (FMHC M&D, FJMC, and KEMC) were explored in a period of three years (2001-2003). In twelve right lower limbs out of seventy-eight Sciatic nerve was found to be dividing in the pelvis. In 08 cases the common peroneal nerve passed through the piriformis, in 01 limb the common peroneal nerve passed above the piriformis, and in 03 cases the nerve passed below the piriformis muscle (Table 1). The Sciatic nerve as per our observations divided in the pelvis after emerging from the sacral plexus. The Common peroneal nerve entered the gluteal region by passing through the

piriformis muscle, while the tibial nerve left through an infra-piriformis foramen. The length of Tibial nerve measured below the piriformis was 35 inches with a diameter of 3.0 cm, the common peroneal nerve that passed through the piriformis was found to be 18 inches long with a diameter of 1.25cm.

Table 1: Total limb explored

Division of Sciatic nerve	=n	%
Normal division	66	85
Variations	12	15
Common peroneal passing above the piriformis	01	08
Common peroneal passing through the piriformis	08	66
Common peroneal passing below the piriformis	03	25

In gluteal region, the two nerves were posterior to the two-gemelli obturator internus and quadratus femoris muscle.

In the back of thigh the nerves traversed the hamstring compartment with the Tibial nerve overlapped by the hamstrings in the upper part, and became superficial in the superior part of the popliteal fossa with the popliteal vessels medial to it. Distally in the fossa the junction of the two heads of gastrocnemius overlapped it. The common peroneal nerve descended obliquely in the popliteal fossa to the head of fibula medial to the tendon of biceps femoris and was lying between its tendon and lateral head of gastrocnemius. It curved lateral to the fibular neck and divided into its two terminal branches the superficial and deep peroneal nerves. Fig.1

In the leg and foot the course and branches of tibial and common peroneal nerve were the same as described in the standard textbooks of anatomy^{1,2}.

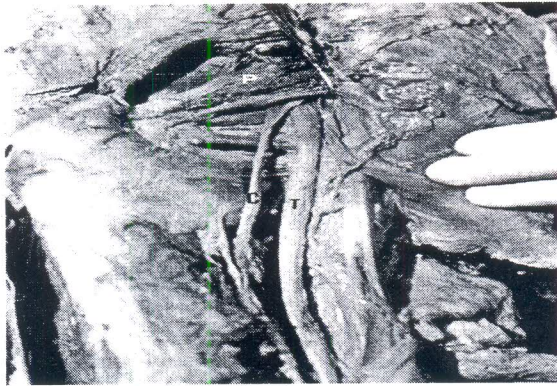


Fig 1:

Discussion

The Sciatic nerve measuring 4cm is the broadest nerve of the sacral plexus. The sciatic nerve usually passes beneath the piriformis muscle to enter the gluteal region. An anomalous sciatic nerve can often be damaged by a wrongly placed intra-muscular injection, its atypical course over the piriformis can also be important for diagnosis and treatment of neuralgia⁴.

An unusual course of sciatic nerve especially through the piriformis muscle results in extra-pelvic entrapment of the nerve^{5,6}, piriformis syndrome^{7,8} and gemellus superior syndrome⁹. In 1928, Yeoman reported the first case relating the piriformis muscle to the sciatic pain. The piriformis muscle syndrome has been described as an abnormal condition of the piriformis muscle characterized by signs and symptoms due to sciatic nerve entrapment at the greater sciatic notch. The etiology of this syndrome is thought to be an injury of piriformis muscle, as well as an abnormal sciatic nerve that passes through the muscle¹⁰. The patient with unremitting sciatica may be suffering with a piriformis syndrome^{11,12}. Since this syndrome is not common it is often overlooked and needless surgery may result.

Functional tests for piriformis syndrome should be routine part of the physical examination of all patients presenting with lower spinal back pain. The complication in identifying piriformis syndrome is the anatomical variation in the sciatic nerve, which can be distinguished only through MRI or exploratory surgery¹³.

The abnormal sciatic nerve may be overlooked while giving a local anesthetic agent in surgical removal of cysts or tumors in the back of thigh or popliteal fossa². A branch of sciatic nerve may remain un-anaesthetized, resulting in pain while performing the procedure.

Lower extremity tumors are often treated by amputation rather than limb sparing excision that sacrifices the sciatic nerve or a branch. A study held in the Department of surgery, Memorial Sloan-Ketleing Cancer center, Newyork¹⁴ assessed the functional out come of the major nerve sacrifice during limb sparing resections for lower extremity soft tissue sarcoma. A patient with an

abnormal high division of sciatic nerve can undergo surgery of only one of the branches and amputation can be avoided. Computerized axial tomography and magnetic resonance imaging¹⁵ of this region is very helpful for accurate diagnosis of sciatica, Piriformis syndrome and Gemellus superior syndrome.

Ontogeny: According to Machado, F.A., Babinski, M.A., Brasil, F.B, three types of courses could be adopted developmentally by the sciatic nerve¹⁶.

1. The common peroneal nerve pierced the muscle and the Tibial nerve passed below the piriformis muscle
2. The Common peroneal nerve passed over the superior margin and the Tibial nerve below the inferior margin
3. The Sciatic nerve passed below piriformis muscle, without any division

Conclusions

The incidence of pelvic division of sciatic nerve is fairly common. So, while establishing the diagnosis of sciatica, extra-pelvic compression of sciatic nerve must not be missed by the clinicians.. These techniques should also be availed before giving a local anesthetic agent.

References:

1. Gray H: Anatomy of the human body. 26th ed. Philadelphia: Lea and Febiger 1956:541
2. Moore K.L.:Clinically Oriented anatomy Baltimore. Williams and Williams 1995 pg.298-395
3. Grant Boileau,J.C (1944) A method of anatomy 3rd ed. The Williams and Wilkins company, Baltimore
4. Jiti Charamza, Libor Machalek. A contribution to the anomalous penetration of the sciatic nerve through the greater sciatic foramen, vol.141, 1998
5. Stewart J.D., Compression and entrapment neuropathy in Dyck and Thomas, Disease of the peripheral nervous system, vol.2: 69
6. Hughes S.S., Goldstone M.N., Hicks D.G., Pellegrini V.D. Jr., Extrapelvic compression of the sciatic. An unusual cause of pain about the hip: Report of five cases. J Bone Joint surg. AM 1992;74:1553-9
7. Vandertop W.P., Bosma W.J., The piriformis syndrome. A case report. J Bone Joint surg. Am.1991;73:1095-7
8. Synek V.M., The piriformis syndrome: Review and case presentation. Clin. And Exper. Neurol.1987;23:31-37
9. Mas N., Ozeksi P.,A case of bilateral high division of sciatic nerve, together with a unilateral unusual course of tibial nerve. A case report. Neuroanatomy.2003;2:13-15
10. Dawson, D.J., Hallett. M: Wilbourn, A Entrapment Neuropathies, 3rd ed., Lippincott-Raven 1999
11. Hallin R.P. Sciatic pain and piriformis muscle. Postgrad. Med.1983;74:69-72
12. Chen W.S., Wan Y.L.,Sciatica caused by piriformis muscle syndrome:Report of two cases.J Formos. Med. Alloc.1992;91:647
13. Palliyath S,Buday J. Sciatic nerve compression :diagnostic value of electromyography and computerized tomography. Electromyogr clin Neurophysiol.1989;29:9-11
14. Brooks A.D., Gold J.S., Graham D, Resection of Sciatic,peroneal, or tibial nerves: assessment of functional status
15. Jankiewicz J.J., Hennrikus W.L.,Houkom J.A.,The appearance of the piriformis muscle syndrome in computed tomography and magnetic resonance imaging. A case report and review of the literature.Clin Orthop. 1991;262:205-9
16. Machado,F.A., Babinski,M.A., Brasil,F.B. et al. Anatomical variations between sciatic nerve and piriform muscle during fetal period in human. Int. J. Morphol., Mar. 2003, vol.21,no.1:29-35.ISSN0717-9502