

Transversely Meshed Skin Grafting for Aesthetically Sensitive Areas

M N TARAR F MEHMOOD A RIAZ Z U KHAN K KHALID F SHER

Department of Plastic Surgery, Allama Iqbal Medical College / Jinnah Hospital, Lahore

Correspondence to Dr. Moazzam Nazeer Tarar, Assistant Professor, E-mail: mntarar@yahoo.com.

Objective: Meshing of split thickness skin grafts (SSG) improves the chances of their 'take' by allowing blood and exudates to escape. Traditional wide meshing has a major disadvantage of having a cosmetically compromised checkerboard or lizard skin appearance. For which reason they can not be used on aesthetically sensitive areas like head and neck and extremities. Unmeshed SSG does not ensure adequate drainage and at times results in poor 'take'. Transverse meshing ensures better drainage and its cosmetic appearance is also comparable to that of unmeshed SSG. The objective of this study has been to analyze the advantages of this novel technique in skin grafting and see its efficacy over un-meshed grafts. **Design:** An original article based on a prospective, observational study. **Methodology:** A total number of 69 patients were studied between October 1999 and April 2003. Both male and female patients of all age groups were selected, ranging between 1^{1/2} and 70 years. Patients selected for skin grafting included those with wounds caused by burns, degloving injuries of the scalp, genitalia, hands and feet and post burn contractures of the neck and extremities, and flap donor sites (see table below). Skin grafts were harvested with a pneumatic dermatome. A mesher board of 1.5: 1 expansion was cut into two equal halves which were placed side by side with the grooved side up. Skin grafts were applied and secured in the standard fashion. The patients were followed up on outpatient basis. **Results:** Graft success rate was 93% with acceptable cosmetic appearance. There was a total loss of two grafts (2.7%) and partial loss of three (4.3%). The healing of the graft was excellent. **Conclusions:** Transverse meshing is a new technique in meshed skin grafting with improved 'take' and acceptable cosmesis as compared to unmeshed skin grafts. This technique can obviate the need for two-stage skin grafting for areas where wide meshing is not desirable.

Key words: Skin Grafts, Transverse meshing, Cosmesis

Split thickness skin graft (SSG) is the most commonly employed reconstructive procedure in cases of skin and soft tissue loss.¹ One major impediment in the 'take' of SSG is collection of blood and exudates beneath the graft. Meshed split thickness skin grafts have become popular because of good drainage. Meshing increases surface area, prevents collection of haematoma and seroma fluid and therefore improves the 'take' of the graft. However, one major disadvantage is poor cosmetic result as compared to unmeshed grafts. The widely meshed grafts give a 'lizard' skin or checkerboard appearance.^{2,3} To overcome this, a technique is being described to mesh the skin graft in a transverse fashion which does not expand the graft but cuts small holes in it which prevent collection of blood and exudate. It combines the advantages of good drainage with a comparable cosmetic appearance. It is particularly useful over areas like face, neck, and extremities.

Materials and methods:

The study was conducted at the Department of Plastic Surgery Jinnah Hospital Lahore extending over a period of three and a half years. A total number of 69 patients were treated with transversely meshed split thickness skin grafts. The indications for surgery are given in the table below. (Table)

Both male and female patients of all age groups were studied ranging from 1^{1/2} to 70 years. All wounds were cultured before grafting to rule out infection with beta-hemolytic *Streptococcus* group A. Burn wounds were grafted as a part of early management of burns. The actual

procedure of preparing a transversely meshed skin graft is as follows.

Surgical Technique: Skin grafts are harvested using Zimmer[®] Pneumatic Dermatome set at 0.012 to 0.015 inch thickness depending on the requirement and the availability of the donor area. Zimmer[®] mesher (Fig. 1) is used for transverse meshing of split thickness skin graft (SSG). The Zimmer Dermacarrier[®] mesher board with an expansion ratio of 1.5 to 1 is used after cutting it into two equal halves (Fig. 2). A sheet of SSG is spread over the ridged side of the mesher board with the dermal side facing up. The board is loaded between the mesher rollers with the ridged pattern orientated transversely (Fig. 3). If the sheet of SSG to be meshed is longer than the length of the mesher board, the board can be recycled once it has gone through the rollers. The meshed graft prepared with this technique has fine, uniform fenestration (Fig. 4) which allows fluid to escape easily from underneath the graft. The skin graft is applied over the wound (Fig. 5, 6) after preparing the bed in the usual manner. The wound is dressed with tulle gauze, fluffed cotton gauze, cotton and finally crepe bandage. Wounds over the head and neck areas are covered with Latex foam contoured to the shape of the defect and secured with skin staples. Similarly, wounds on the hands are splinted with plaster of Paris slabs and are elevated.

Results:

Between October 2001 and April 2005, a total of 69 transversely meshed skin grafts were performed. The age range was 1^{1/2} to 70 years, with a male to female ratio of

2.7 to 1. The follow up period ranged between 24 to 41 months with a mean of 32.5 months.

There was near-total loss of the graft in two patients requiring re-grafting. There were three incidents of a small loss of graft at the margins due to graft movement during the immediate post-operative period. No mortality occurred during the study. The healing of the graft was excellent with acceptable cosmetic appearance.

Table: Indications for operation.

Indications	=n
Scalp injuries	11
Wounds over hands and feet	17
Peno-scrotal injuries	9
Post-burn contractures	26
Flap donor areas	6

Discussion:

Split thickness skin grafts provide an important source of wound cover and healing by primary intention of large wounds that would otherwise heal with extensive scarring and deformity.^{4, 5} Collection of blood and exudates underneath the graft is a major cause of its loss.^{6, 7} Meshing has revolutionized the grafting of large defects. Meshing cuts small holes in the sheet of skin graft at regular intervals and when stretch is applied, the graft expands and the amount of expansion is proportionate to the size of cuts in the graft. The graft can be expanded from 1.5 to 9 times, depending upon the mesher board used. In this way, much larger areas can be covered with relatively small amount of skin graft.

The main disadvantage with the mesh is its cosmetic appearance, the pattern of the original mesh remaining visible even after the graft has healed. The checkered appearance of the widely meshed graft is due to absence of the dermal component of the graft over the meshed space. These areas heal by spread of the epidermis and have difference in appearance from the areas where the dermis is present. This restricts the use of meshed grafts to relatively unexposed areas and application over cosmetically sensitive areas becomes impossible, and this is where the use of an unmeshed graft becomes imperative.^{1, 2} The disadvantage of unmeshed grafts is the risk of their loss by the collection of blood and exudates. Different techniques of hand meshing have been described to avoid this complication⁹ but these are time consuming and the holes in the mesh are not uniform in size and distribution. This increases the chances of areas of haematoma collection under the graft and its subsequent loss.

Collection of blood and serum under the graft is so much feared a complication that two-staged skin grafting is recommended and practiced for areas where traditionally meshed grafts are not desirable.^{6, 7} In the first stage, the scar or burn wound is excised and haemostatic dressing is applied. 48 hours later, an SSG is applied unmeshed to achieve good graft 'take' avoiding collection underneath.

Transverse meshing can obviate the need for two-staged procedures.

In our technique the holes in the mesh are uniformly cut and spread over the graft so that there are less chances of haematoma and exudates being collected. Meshing in the transverse direction cuts holes in the graft horizontally which helps improve the 'take' of the graft by letting blood and serum exude through them, yet the graft retains the cosmetic properties of the unmeshed graft because transverse meshing leaves these spaces too narrow so that the areas of the graft devoid of dermis are barely visible. This fact is responsible for the improved appearance of transversely meshed skin graft. This extends the use of meshed skin grafts to areas that were previously unsuitable for it such as face, neck, hands and feet.

Conclusion:

Transverse meshing is a novel technique which can extend the use of meshed grafts over areas that are aesthetically sensitive. This technique will improve the 'take' of the graft without compromising its cosmetic appearance.

References:

1. Rudolph, R., and Ballantyne, D.L: Skin grafts. In McCarthy, J. (Ed.): Plastic Surgery. Philadelphia, W.B Saunders, 1990.
2. Converse JM, et al. Inosculation of vessels of skin graft and host bed: a forfeitures encounter. Br J Plast Surg, 1975; 28:274
3. Eroglu L, Uysal OA. An easy and effective method for preparing meshed skin grafts. Plast. reconstr. Surg. Sept 15 2001, 108(4).
4. Granick MS, Wind S, Solomon MP: Wound management and wound care. In Habal MB (ed): Advances in Plastic and Reconstructive Surgery, Vol 12, St. Louis, Mosby Year Book, 1996, pp 99-121
5. Robson MC, Smith DJ. Burned Hand. In: Jurkiewicz MJ (ed) Plastic Surgery: Principles and Practices: St. Louis, MO: C.V. Mosby Co., 1990
6. Demling R, DeSanti L. Management of partial thickness facial burns. Burns 1999; 25 (3): 256-61
7. Gordon M. Burn Care Protocols: Infection Control. J Burn Care Rehab 1997; 8: 67-71




Fig. 1: Zimmer Dermacarrier® Mesher Board placed transversely.




Fig 2. Mesher Board being cut across into two equal halves.




Fig 3. Transverse loading of the board with skin graft




Fig 4. Transversely meshed graft.

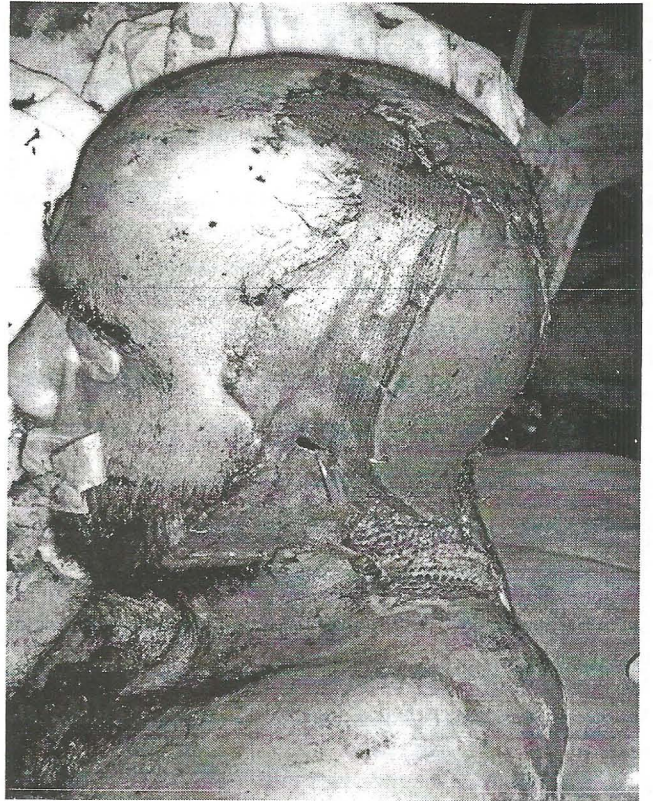

Fig 5. Transversely meshed graft over the face vs. widely meshed graft over nape of the neck

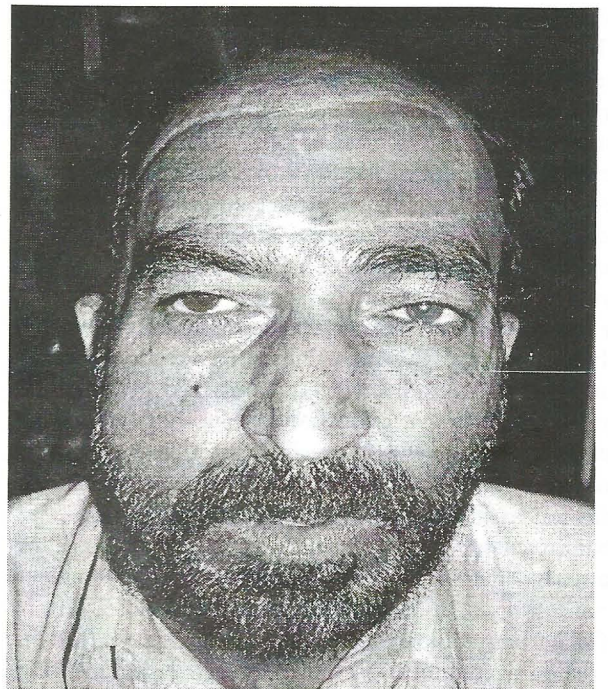


Fig. 6 Transversely Meshed skin graft applied over flap donor site on forehead