

## Case Report

# Third Nerve Paralysis due to Cranial Metastasis of Prostate Tumor

R MR QAMAR Q MANSOOR T MAJEED

Department of Ophthalmology, B.V. Hospital / Quaid-e-Azam Medical College, Bahawalpur

Correspondence to Dr. Rao Muhammad Rashad Qamar, E-mail: drrashadqr@yahoo.com

Brain metastasis is rare in prostate cancer and occurs late in the course of the disease caused by hematogenous spread. They often affect the posterior pole of fundus. We report a case of third nerve palsy secondary to bony metastasis in the cranium.

### Case Report:

A 90 years old man presented with outward deviated right eye with droopy lid. These symptoms were developed over a period of two weeks and there was no pain behind the eye. There was no previous history of Diabetes mellitus, hypertension etc. He had a treatment for adenocarcinoma of prostate six years ago.

On examination his best-corrected visual acuity was 6/60 in each eye. There was right complete third nerve paralysis with pupil involvement. Anterior segment examination showed nucleosclerotic changes on both sides. Posterior segment examination showed ARMD (dry type) in both eyes. Intraocular pressure and discs were normal.

Contrast enhanced MR scan brain revealed a destructive mass at the base of skull at petrous apex on the right side extending forward to orbital apex on the same side (Figure 1 & 2). Total body bone scan also showed multiple metastatic lesions. Patient was referred to oncology unit for further management

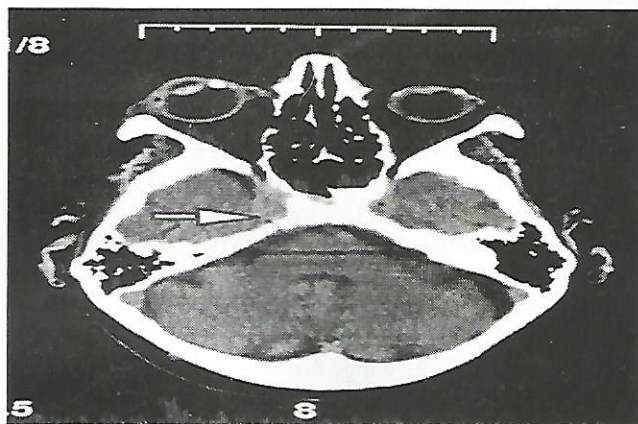
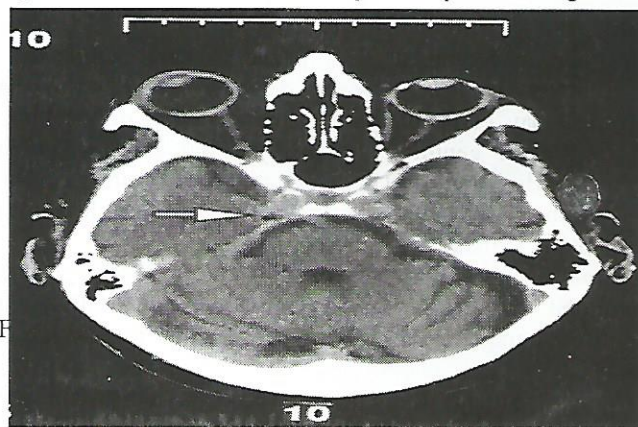
### Comments:

Prostate cancer is second only to lung cancer as the leading cause of cancer relating deaths in men. Average time from the diagnosis of prostate cancer to the occurrence of metastasis is 19 months for bone metastasis, 35 months for lung metastasis and 60 months for brain metastasis<sup>1,2</sup>. Less than 1% of prostate cancer metastasise to brain Most common intracranial sites are leptomeningis (67%), cerebrum (25%), and cerebellum (8%)<sup>2</sup>. Metastasis usually represents the failure of hormone deprivation therapy and presence of disseminated disease<sup>2</sup>. Cranial metastasis is associated with poor prognosis. . Once prostate cancer has spread to brain, the one-year survival rate is 18%<sup>3,4</sup>. For diagnosis no test other than gadolinium-enhanced MRI is required to exclude or confirm the presence of brain metastasis<sup>5</sup>.

Patients with prostate cancer rarely present with bony cranial metastasis and so far in our knowledge no case has been reported presenting as third nerve palsy as the result of bony cranial metastasis. Lesions in the neighbourhood of posterior clinoid process as appeared in this case may for some time affect only the third nerve as it pierces the

dura. Therefore, among other causes of third nerve paralysis lesion at petrous apex/posterior clinoid process should also be considered as a rare cause.

Figure 1 and 2: Destructive mass at petrous apex on the right side



### References:

1. Landis SH, Murray T, Bolden S, Wingo PA, Cancer statistics. CA Cancer J Clin 1999; 49:8-31.
2. Lynes WL, Bostwick DG, Freiha FS, Stamey TA. Parenchymal brain metastasis from adenocarcinoma of prostate. Urology 1986; 28:280-7.
3. Gupta A, Baidas S, Cumberlin RK. Brain stem metastasis as the only site of spread in prostatic carcinoma, A case report; 74:2516-9.
4. Ferveza FC, Wolanskyj AP, Eklund HE, Richardson RL. Brain metastasis: An unusual complication from prostatic adenocarcinoma. Mayo clinic Proc 2000; 75:79-82.
5. DeAngelis LM. Metastatic diseases of nervous system. Current treatment options neurol. 1999; 1:409-16.

## Case Report

### Vulval Mass

N SHAMI SANWAR IAKMAL S ASIF

Department of Obstetrics & Gynaecology, Lahore Medical & Dental College/ Ghurki Trust Teaching Hospital, Lahore  
Correspondence to Dr. Nabeela Shami, Associate Professor.

Miss T, daughter of G. N., 25 years of age presented with history of swelling of the right side of the vulva for last 3 years. On examination a large growth arising from the labia majora and hanging down to just below the knee was seen. Excision of the vulval growth was done. Histopathology revealed fibroepithelial polyp.

**Key words:** Vulval mass

Vulvovaginal problems are among the 10<sup>th</sup> leading disorder encountered by primary care clinicians.<sup>1</sup> Definitive diagnosis may be delayed even though the woman may complain of pruritis, irritation or swelling. The external genitalia can also be the site of benign growth.<sup>2</sup> Both **lentigo** (freckles) and **nevi** (moles) can be found on the labia and must be clearly distinguished from melanoma. Often excisional biopsy is needed.

**History:** Miss T, daughter of G.N., 25 years of age was admitted through Outpatient Department on 10.09.2003 with the complaint of growth on the vulva for the last 3 years.

The patient was all right 3 years ago when she noticed a swelling on the right side of the vulva. This swelling gradually increased in size. It was not accompanied by any itching or pain. There was no history of any vaginal discharge or pruritus, no history of any urinary or bowel complaints.

She had no previous history of hospitalization, surgery or any chronic ailment. Her age of menarche was 13 years with 4-5/ 28 days cycle with average flow and mild dysmenorrhoea. Her last menstrual period was 05-09-2003. Her mother was hypertensive, no history of tuberculosis, diabetes mellitus or malignancy was present in the family. She belonged to poor socio-economic class and worked as a maidservant. There was no history of smoking or betel chewing. No known drug allergies or history of taking any drugs.

On examination, she was a young girl, well oriented in time and space, sitting in bed. She was intelligent and cooperative. Her BP 110/70mmHg, pulse 86/ min, regular, full volume, temperature normal, pallor, cyanosis, clubbing, koilonychias not demonstrated. Thyroid gland not enlarged. Cervical, axillary and inguinal lymph nodes were not palpable. Breast examination revealed no abnormality. Examination of CVS, respiratory system and CNS did not reveal any abnormality.

On abdominal examination, abdomen was symmetrical and moving with respiration. No scar marks or visible veins were seen. Umbilicus was central and inverted. There was no area of tenderness on superficial palpation. Liver, spleen and kidneys were not palpable.

**Pelvic examination** revealed a large growth arising from the right labium majus and hanging down to just below the

knee was seen. The pedicle of the growth was 10x7cm at the base. The length was 30cms. No discharge was seen at the introitus. Hymen was intact. Speculum and vaginal examination were not done.

**Investigations:** Blood group and Rh factor O +ve, Haemoglobin 10.6 gm/dl, Blood sugar random 86 mgs/ dl, Abdominopelvic ultrasonography revealed a normal size anteverted uterus with ovaries showing follicular activity. No mass or fluid was seen in the cul-de-sac.

**Procedure :** Excision of the vulval growth was done under general anaesthesia. Patient was put in lithotomy position. The vulva was painted with pyodine. Foley's catheter No 16 was passed; and patient was draped.

An elliptical incision was made on the base of the pedicle. Skin was undermined. The pedicle was clamped, cut and ligated. Small bleeding points were cauterized while a few larger vessels were tied separately. Skin was closed by silk No. 0. Specimen was sent for histopathology.

Post operative period was uneventful. Catheter was removed after 24 hours. The patient was discharged on 4th post operative day and advised to report on 10th post operative day for removal of stitches. Stitches were removed on the 10<sup>th</sup> day and the wound was healthy. Six weeks follow up showed a healed scar on the right labium majus. Histopathology revealed **fibroepithelial polyp**

#### Discussion:

**Fibromas** are the most common benign solid tumours that form in the deeper connective tissue of the vulva. Although fibromas are slow growing and most are 1 to 10 cm. They can become gigantic (> 250 lb)<sup>3</sup>.

**Lipomas** are also slow-growing tumours of the vulva composed of adipose cell. Other tumours derived from tissue found in external genitalia, such as **hidradenoma** (sweat gland tumour). This is seen mainly in women in late 20s to 50s. This lesion is usually solitary and overlying skin may appear umblicated<sup>4</sup>. Excisional biopsy confirms the diagnosis and is the treatment.

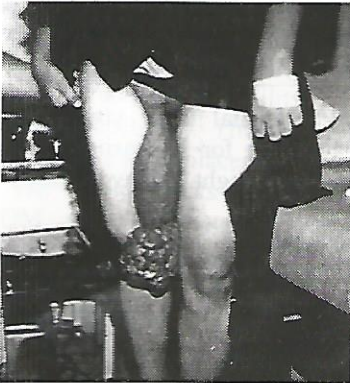⇒ **Syringoma** (eccrine gland tumour)

⇒ **Granular cell myoblastoma** (neural sheath Schwann cell tumour)

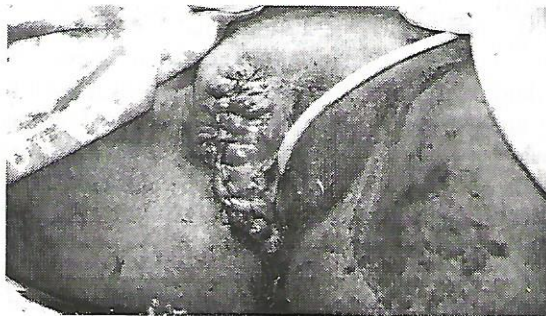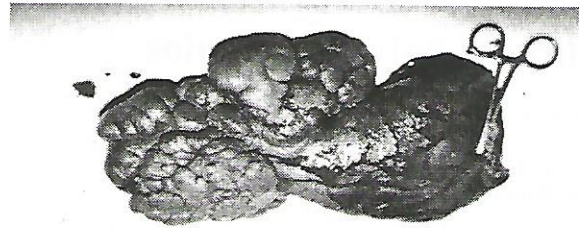
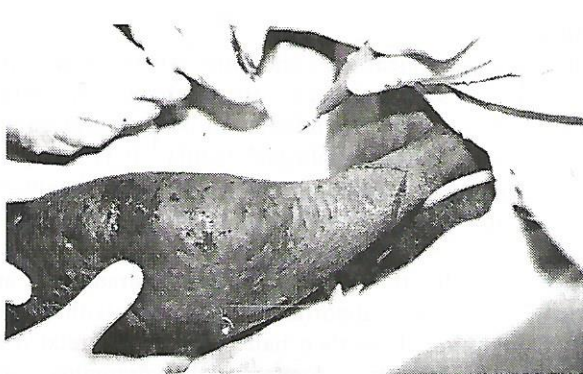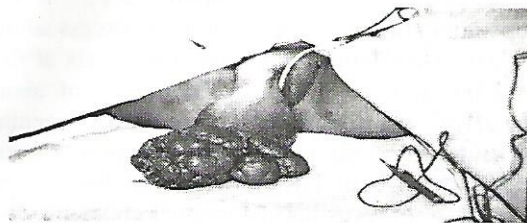
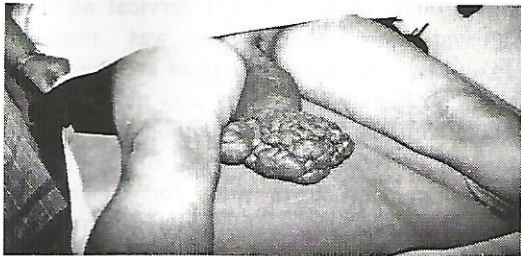
⇒ **Neurofibroma** (from von reckling-hausen disease)

Definitive diagnosis of lower genital tract lesions require biopsy and are removed surgically if they cause problem.

**Haemangiomas**<sup>5</sup> do not attain large size and usually appear in the 4<sup>th</sup> or 5<sup>th</sup> decade of life. Squamous cell carcinoma of the vulva can present as a lump but pruritis is common<sup>6</sup>. Most lesions occur on the labia majora but less commonly on the clitoris or perineum<sup>7</sup>. Usually the malignant lesion do not reach such massive proportions.



Courtesy: Department of Pathology, LM&DC, Lahore



### Conclusion

A tumour of such a large size is unusual and rare. Diagnosis and treatment were delayed due to poverty and uneasiness associated with the site of the lesion.

The lesions of large size on the vulva are benign most of the time and excision results in both confirming the diagnosis and is the treatment.

### References

1. Anita L. Nelson and Joseph C. Gambone; Congenital anomalies and benign conditions of the vulva and vagina. In: Hacker et al. Essentials of Obstetrics & Gynaecology 4<sup>th</sup> edition; WB Saunders, Philadelphia 2004. Pg. 259.
2. Anita L. Nelson and Joseph C. Gambone; Congenital anomalies and benign conditions of the vulva and vagina. In: Hacker et al. Essentials of Obstetrics & Gynaecology 4<sup>th</sup> edition; WB Saunders, Philadelphia 2004. Pg. 262.
3. Thomas B. Lebherz; Infectious and benign diseases of vagina, cervix and vulva. In: Neville F. Hacker J. George Moore (ed). Essential of Obstetrics & Gynaecology; 3<sup>rd</sup> Ed; W.B. Saunders, Philadelphia 1998; pg. 393-411.
4. Fox H. Buckley CH, 1988; Non epithelial and mixed tumours of the vulva. In: Ridley CM (ed) The vulva. Churchill Livingstone, Edinburgh PP 235-262.
5. Fredrich EG, 1983; Vulvar disease, 2<sup>nd</sup> Ed. Saunders Philadelphia.
6. Cavanagh D, Ruffolo EH, Marsden DE, 1985; Cancer of the vulva. In: Cavanagh D, Ruffolo EH, Marsden DE (Ed) Gynaecologic Cancer – a Clinicopathologic Approach Appleton – Century – Crofts, Connecticut, pp 1-40.
7. Fredrich EG, Wilkinson EJ, 1982; The vulva; In Blanstain A (ed) Pathology of female genital tract; 2<sup>nd</sup> Ed, Springer Verlag, New York pp 13-58.

## Case Report

# Recurrent Polyhydramnios

E SHAHID M S MUBARIK

Department of Obstetrics & Gynaecology, Lady Aitcheson Hospital, Lahore

Department of Medicine, Mayo Hospital, Lahore.

Correspondence to Dr. Erum Shahid

**A case study of recurrent polyhydramnios of unknown aetiology who delivered an alive normal baby at 35 weeks of gestation.**

**Key words: Polyhydramnios, Recurrent, Pregnancy.**

Polyhydramnios detected in pregnancy should be investigated thoroughly. Chromosomal abnormalities should be excluded. Polyhydramnios is an excess of amniotic fluid. It is a common occurrence which is usually related to congenital foetal anomalies, Diabetes Mellitus [DM], twin pregnancy, idiopathic etc., but recurrent polyhydramnios is a rare event. Index of amniotic fluid greater than 24 and with associated symptoms such as abdominal discomfort, respiratory distress, and premature uterine contractions & abdominal pain.

Polyhydramnios carries a poor foetal prognosis with an expected neonatal death rate of nearly 30%. One fourth of this perinatal mortality is a result of the effects of prematurity<sup>1</sup>.

Indomethacin 2.2 -3mg/kg/day p.o. 6 hourly until symptoms disappear and the index of amniotic fluid is less than 24 require close monitoring of foetal heart. USG control should be obtained every 24 hours & foetal echocardiography at 24 & 96 hrs of treatment. Indomethacin shows no maternal or foetal side effects if used with close monitoring<sup>2</sup>. Therapeutic amniocentesis is another mode of treatment. Complications are; rupture of membranes, chorioamnionitis, and abruption. Complication rate is 1.5%

### Case Report:

A 28yrs old woman G4P2A1 married for eight years was diagnosed as a case of polyhydramnios in successive pregnancy. Regarding her past obstetrical history she had polyhydramnios in her last pregnancy which ended up in premature labour at 30 wks of gestation and the baby expired 3 days later due to prematurity. Baby had no congenital abnormalities. She was booked in Lady Aitcheson Hospital in early 2<sup>nd</sup> trimester. She presented with h/o pain & sensation of dragging weight in lower abdomen. Upon taking detailed history she complained of spotting off and on in 1<sup>st</sup> trimester. She took medicine from Hakim for ovulation. Midtrimester scan was done on 11.05.004 which showed BPD 3.6cm F.L 2.0cm & GA 16.4wks and an incompetent cervical os [cervical dilation and shortening both present] with single alive foetus with adequate liquor. S.K. stitch was applied. Placenta was upper segment with no gross foetal anomaly. BSR 92mg/dl, HCV+, Blood gp +, HBsAg

neg. Patient had regular antenatal OPD visits. USG was repeated at 22wks of gestation for increasing discomfort and larger for dates fundal height. Polyhydramnios with AFI more than 24 was detected.

In 3<sup>rd</sup> trimester she became increasingly dyspnoeic, was unable to lie flat in bed & c/o severe discomfort. Tab. Indomethacin was started at a dose of 25 mg 6hrly. She came in emergency on 20.9.004 at 35+3 wks of GA with h/o leaking p/v for two days. SK stitch was removed.

On per speculum examination clear liquor was found to be draining through slightly dilated cervical os. Two doses of steroid was given. She was managed conservatively and was monitored for signs and symptoms of chorioamnionitis. Foetal well being was monitored by regular CTG, FKK & FHR monitoring. Blood sugar levels were monitored which remained in normal limits. Hb was 10.4mg/dl. She developed fever after forty eight hrs. Labour was induced with mesoprostal 50microgms. After 24hrs of start of induction EmL SCS was performed due to failure of induction and increasing temp of 102°F.

Per-operative findings; liquor was in excess about 1500ml & clear. Alive female with Apgar score six at five minutes and ten at ten minutes. An abruption of about three hundred ml was found. There were no congenital fetal abnormalities. Post op. period was uneventful. Patient was discharged on seventh day after removing the stitches. Follow up at six weeks was normal, mother and baby were healthy.

### Discussion:

Polyhydramnios appear in conditions where swallowing does not occur such as anencephaly, or when gastrointestinal tract is occluded as in oesophageal atresia associated with tracheoesophageal fistula.<sup>3</sup> It is usually a clinical diagnosis although it can be diagnosed ultrasonographically. It signifies an excess of liquor which is likely to affect the course of disease.

About half the cases of polyhydramnios are associated with foetal abnormality especially with barrier to foetal ingestion. Less than half of cases are related to excessive production. Acute polyhydramnios are associated with monozygous twin pregnancies and with large placental chorioangiomas. Recurrent polyhydramnios is a very rare event usually associated with maternal

diabetes mellitus<sup>4,5</sup> and HIV. The mechanism responsible in HIV is not known yet. Any patient with recurrent polyhydramnios should be screened for DM and HIV. Tests for AIDS pose a problem because the patients usually refuse to be tested for HIV, reason being the social stigma and the fear of being left alone. Anonymous testing can be offered or testing whose results are not given to family without patient's consent can be done. This is a way to help the patient if she is HIV positive.

Maternal risks associated with polyhydramnios are mostly due to uterine distension such as abdominal discomfort, uterine irritability, pph and compromised respiratory functions<sup>5</sup>. The incidence of c/s is increased due to unstable lie & placental abruption.

The foetal risks are congenital abnormalities, PPROM, preterm labour and delivery. Transabdominal amniotomy and Indomethacin can be tried to decrease amniotic fluid thereby relieving maternal discomfort. Sulindac, an alternative prostaglandin synthase inhibitor may be safer than Indomethacin. The recommended dose is 200mg BD.

#### Conclusion:

Recurrent polyhydramnios is an extremely rare event, which may be idiopathic<sup>6</sup> or may be associated with maternal diabetes mellitus and HIV.

#### References:

1. Vigil-degraciape, Campos-Rivera P, Lasso-dela Vega J. Pregnancy complicated with symptomatic polyhydramnios: treatment with indomethacin. *Ginecologia y obst. de Mexico*.1997; 65:21-6
2. Cabrol D, Jannet D, Pannier E. Treatment of symptomatic Polyhydramnios with indomethacin. *European Journal of obst, Gynae & Reproductive Biology*: 1997; 66:11-5.
3. Pilu Gianluigi, Nicolaidis Kypros, Ximenes Renato, Jeanty Phillipe. Abnormalities of the amniotic fluid volume. In: *Handbook of Fetal Abnormalities*.
4. Beischer N, Desmedt E, Ratten G, Sheedy M. Significance of recurrent polyhydramnios. *Aust N Z J Obstet Gynaecol*.1993;33:25-30.
5. Abhyankr S, Salvivs. Indomethacin therapy in hydramnios. *Postgrad Med*2000; 46:176-8.
6. De Santis M, Cavaliere AF, Noia G, Masini L, Menini E, Caruso A. Acute recurrent polyhydramnios and amniotic prolactin. *Prenat Diagn*.2000;347-8