

# Morphological Evaluation of Non Neoplastic Lesions of the Thyroid Gland

S NIAZI M H BUKHARI G R QURESHI

Department of Pathology, King Edward Medical University, Lahore Pakistan.

Correspondence to Dr. Mulazim Hussain Bukhari, Assistant Professor [drmhbukhari@yahoo.com](mailto:drmhbukhari@yahoo.com)

**Objective:** This study was conducted to see the frequency of non neoplastic lesions of thyroid glands in patients who underwent thyroid surgery at Mayo hospital, Lahore. **Study design:** It was a descriptive cross sectional study. **Place and Duration of study:** It was a retrospective and prospective study commencing from 1<sup>st</sup> July 1999 to 30<sup>th</sup> June 2002 and was conducted at Pathology Department King Edward Medical University, Lahore. **Materials and methods:** All thyroid samples submitted and reported at the Department of Pathology, King Edward Medical University, Lahore during a three year period commencing from 1<sup>st</sup> July 1999 to 30<sup>th</sup> June 2002 were included in this study. **Results:** Out of the total number of 1136 thyroid surgical specimens, 855 specimens (75.26%) were shown to comprise of non-neoplastic lesions and were more common in females (77.2%) as compared to males (22.8%) giving a male to female ratio of 1:3.4. Regarding non neoplastic lesions maximum comprised of diffuse (74%) and multi nodular goiters (16%). Others consisted of inflammatory conditions (5%), hyperplastic nodules (4%) and simple colloid filled cysts 1%. Inflammatory conditions included Hashimoto's thyroiditis (67.3%) deQuervain's thyroiditis (granulomatous thyroiditis) (16.3 %), Lymphocytic thyroiditis (11.7%), and Riedel's thyroiditis (4.7%). **Conclusions:** Non neoplastic thyroid lesions are more common than neoplastic lesions, especially in females. The frequency of diffuse colloid goiter was very high, while among inflammatory lesions Hashimoto's thyroiditis was the commonest lesion. Most of the cases of hypothyroidism were associated with iodine deficiency.

**Key words:** Diffuse Colloid Goiter, Multinodular goiters, Hashimoto's thyroiditis, deQuervain's thyroiditis, Colloid cysts.

Thyroid enlargement is a common problem faced both by clinicians and histopathologists. Thyroid nodules (TN) are a common clinical problem which occur spontaneously and are present in 4-7% of the adult population<sup>1,2</sup>. Their incidence however, is significantly higher in endemic goitrous regions, in the female sex and with increasing age<sup>3</sup>. These nodules may be due to a variety of underlying pathological conditions, both neoplastic and non-neoplastic. About 90-95% of the neoplastic lesions prove to be benign, usually an adenoma on histological examination and only 5-10% prove to be malignant<sup>4,5,6</sup>.

The most common non neoplastic lesion is goiter which could be due to hyperthyroidism or hypothyroidism. The commonest cause of hyperthyroidism is Graves' disease. Hashimoto's thyroiditis is the predominant inflammatory lesion while subacute granulomatous thyroiditis, postpartum thyroiditis, subacute lymphocytic thyroiditis comprise a minor proportion<sup>7,8,9,10,11</sup>.

Goiter is an enlargement of the thyroid gland that often produces a noticeable swelling in front of the neck. This enlargement can be caused by iodine deficiency, inability of the body to use iodine correctly, or a variety of thyroid disorders, including infection, tumors, and autoimmune disease. Some environmental pollutants, heavy metal poisonings, and certain drugs can also contribute to goiter formation<sup>12,13,14</sup>.

Iodine-deficiency goiter can be common in regions where the soils and foods have insufficient iodine. Preschool children, adolescent girls, pregnant women, and the elderly are most vulnerable to goiter and other iodine-deficiency disorders<sup>15</sup>. Areas where iodine supplies are inadequate show high rates not only of goiter but also of

birth defects and mental and physical retardation<sup>16</sup>. This study was conducted to see the frequency of different non neoplastic lesions of the thyroid on clinicopathological grounds.

## Materials and methods:

This was a descriptive study and was conducted at the Department of Pathology, King Edward Medical University, Lahore in collaboration with the four major Surgical Units of Mayo Hospital, Lahore. All thyroid samples submitted and reported at the Department of Pathology, King Edward Medical University, Lahore during a three year period commencing from 1<sup>st</sup> July 1999 to 30<sup>th</sup> June 2002 were included in this study.

Records of all the previously diagnosed and reported cases on thyroid tissues in the years 1999 (commencing from 1<sup>st</sup> July), 2000 and 2001 were retrieved and reviewed in our research project. The relevant thyroid scans and laboratory investigations of the patients were also included in this study. The record of retrospective cases was collected from computer. In addition all new thyroid surgical specimens submitted in the year 2002 till 31<sup>st</sup> June were also included in our study. The record of these cases was collected from the 4 surgical units of Mayo Hospital Lahore.

Relevant clinical data including patients name, age, sex, history of previous thyroid surgery, etc. were noted and recorded on a proforma. Results were compiled with the help of a computer. SPSS version 8 was used for data analysis and the frequency of various morphological types was calculated as percentages and means. The data was stratified for age and sex and presented in the form of

tables. Our results were then compared with other similar local and international studies.

### Results:

During a period spanning 3 years (commencing from 1<sup>st</sup> July 1999 to 30<sup>th</sup> May 2002), a total of 1136 thyroid surgical specimens were referred from the four surgical units of Mayo Hospital, Lahore to the Histopathology section of the Department of Pathology, King Edward Medical University. These surgical specimens were from both sexes and all age groups. The results are analyzed as follows:

Out of the total number of 1136 thyroid surgical specimens, 855 specimens (75.26%) after routine grossing, processing and reporting were shown to comprise of non-neoplastic lesions like diffuse colloid nodules(74%), multinodular goiters(16%), hyperplastic nodules (4%), simple colloid filled cysts (01%). and inflammatory conditions(05%), which included Hashimotos' thyroiditis (67.3%), deQuervain's thyroiditis (granulomatous thyroiditis) (16.3%), Lymphocytic thyroiditis (11.7%), and Riedel's thyroiditis(4.7%). The remaining 281 (24.74%) cases comprised of neoplastic lesions both benign and malignant. (Table I)

Most of the hypothyroid patients (with high TSH and low T3/T4 level) were associated with iodine deficiency. All cases of Hashimotos' thyroiditis were hypothyroid. Multinodular goiters (MNG) and diffuse colloid goiters (DCG) presented as cold nodules and were euthyroid or hypothyroid (Table I,22) (Fig. I&II)

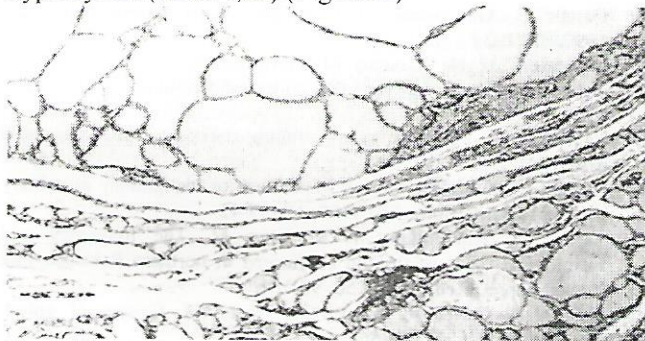


Fig I. Photomicrograph of colloid goiter showing large colloid filled follicles and flattened follicular lining epithelium.

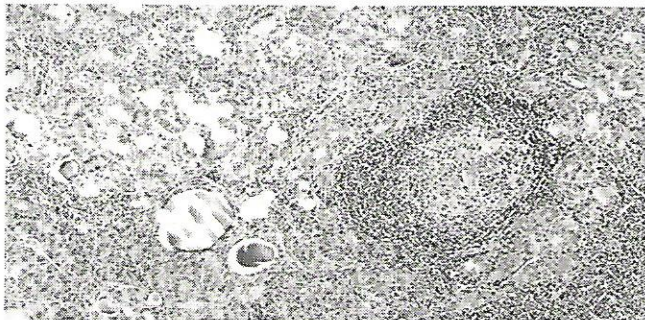


Fig II. Photomicrograph of Hashimoto's thyroiditis, depicting lymphocytic infiltration and oncocytic changes in thyroid tissue.

Table I. Distribution of various Thyroid Lesions (n=1136)

Category	n	%age
Non-neoplastic lesions	855	75.26
Tumors	281	24.74

Table II. Distribution of various non neoplastic lesions of Thyroid

Lesion (n=855)	Male (n=195) 22.8%	Female (n=660) 77.2%	Total	%age
	M:F=1:3.4			
Diffuse colloid goiter	138	496	634	74.15
Multinodular goitre	30	106	136	16
Thyroiditis	15	28	043	05
Hyperplasia	10	24	034	04
Cysts	02	06	08	01
Total	195	660	855	

Table III. Morphologic Distribution of Thyroiditis

Lesion (n=43)	Male (n=15)	Female (n=28)	Total	%age
Hashimotos' thyroiditis	12	17	29	67.3
deQuervain's thyroiditis (Granulomatous thyroiditis)	02	05	07	16.3
Lymphocytic thyroiditis	01	04	05	11.7
Riedel's Thyroiditis	-	02	02	4.7
Total	15	28	43	

### Discussion:

Despite its structural simplicity, the thyroid gland can give rise to a large variety of pathologic lesions, both neoplastic and non-neoplastic which usually present clinically as diffuse swellings (goiter) or as discrete palpable solitary nodules<sup>1,2,17</sup>. In our 3 years study at KEMU/Mayo Hospital, Lahore, about 75% of the thyroid surgical specimens referred for histopathological evaluation were found to be non-neoplastic lesions of which the commonest was colloid goiter. Neoplasms or tumors including both benign and malignant constituted 25% of the total surgical specimens.

In a study conducted by Ahmad and coworkers<sup>18</sup>, neoplastic lesions constituted 31% and non-neoplastic lesions 69% of his cases. However, a study conducted by Sarfraz<sup>19</sup> in the northern areas of Pakistan which constitutes the goiter belt shows a much higher frequency of the non-neoplastic lesions (89.5%) including goiter, as compared to the neoplastic lesions or tumors which account for 10.5% of the cases. Our figures do not differ substantially from the figures quoted by Navid and associates<sup>(20)</sup>, in which during a 5 year period, non-neoplastic thyroid lesions constituted 71.10%.

In our study most of the lesions were multinodular or diffuse colloid goiter and these presented as cold nodules. Iodine deficiency was seen in cases suffering from hypothyroidism and T3/T4 levels were also low in inflammatory lesions. In 34 cases of hyperplasia very few cases were associated with thyrotoxicosis; however most of the cases of hyperthyroidism were reported as hot nodules on scan. Thyroid profile showed high T3/T4 and low TSH level in hyperthyroid patients. Our findings are consistent with the findings of Bisi et al(1998)<sup>11</sup> and also similar with the findings of Ambreen et al (2005)<sup>21</sup> who concluded that multinodular goiter is the commonest non

neoplastic thyroid lesion in the general population and all thyroid lesions whether neoplastic or non neoplastic are more common in females.

Regarding inflammatory lesions (thyroiditis) which comprised 5% of our total non neoplastic cases, the commonest was Hashimoto's thyroiditis which constituted (67.3%). It was predominant in females and associated with hypothyroidism in all instances. Morphologically it was characterized by an abundant lymphoplasmacytic infiltrate and oncocytic changes in the follicular epithelium. These findings are in accordance with the work of Bindra and Braunstein, who also concluded that Hashimoto's thyroiditis is the commonest thyroiditis and associated with hypothyroidism (2006)<sup>22</sup>.

All the 7 cases of de Quervain thyroiditis were associated with hypothyroidism with low T3/T4 and high TSH level. Morphologically all these cases were associated with marked mixed cellular inflammation, giant cell formations and mild fibrosis. AFB was performed to differentiate from tuberculosis but was negative in all cases. Both cases of Riedel's thyroiditis were seen in females and associated with dyspnea. On morphology there was extensive fibrosis with scanty thyroid residual tissue and mild lymphocytic infiltration. All the 5 cases of Lymphocytic thyroiditis seen in children of 10-16 years. T3/T4 level was slightly high but normal TSH. Morphologically there was diffuse lymphocytic infiltration with formation of lymphoid follicles and germinal center. The thyroid tissue was unremarkable. The finding of our study are not different as reported in previous literature as described by Rosai et al (2004)<sup>23</sup>.

#### Conclusions:

Non neoplastic thyroid lesions are more common as compared to neoplastic lesions in a ratio of 3:1. There was a marked female preponderance (M:F ratio 1:3.4). Multinodular goiter was the commonest diagnosis. Microscopic examination remained the gold standard for the ultimate diagnosis. The results and the relative efficacy of the various diagnostic modalities are discussed. The frequency of diffuse colloid goiter was greater than MNG while among inflammatory lesions Hashimoto's thyroiditis was more common. Most of the cases of hypothyroidism were associated with iodine deficiency or thyroiditis. The prevalence of thyrotoxicosis was low in this study.

#### References:

1. Vander JB, Gaston EA, Dawber TR. The significance of non toxic thyroid nodules. *Ann Int Med* 1968; 69: 537-40.
2. De Lellis RA. The endocrine system (thyroid gland) In: Cotran RS, Kumar V, Robbins SL, editors. *Robbins Pathologic basis of disease*, 4<sup>th</sup> ed. Philadelphia: Saunders, 1989: 1214-42.
3. Kumar V, Collins T. The endocrine system (thyroid) In: Cotran RS, Kumar V, Robbins SL, editors. *Robbins Pathologic basis of disease*, 6<sup>th</sup> ed. Philadelphia: Saunders, 2004: 1130-47.
4. Gharib H, Goellner JR. FNAB of the thyroid: an appraisal. *Ann Int Med* 1993; 118:282-90.
5. La Rosa G L, Belfiore A, Guiffrida D, Sicurella C, Ippolito O, Russo G et al. Evaluation of the FNAB in the pre-operative selection of cold thyroid nodules. *Cancer* 1991; 67:2137-41.
6. Layfield LJ, Mohrman RL, Kopold KH, Guiliano AE. Use of aspiration cytology and frozen section examination for management of benign and malignant thyroid nodules. *Cancer* 1991; 68:1
7. Reid JR, Wheeler SF. Hyperthyroidism: diagnosis and treatment. *Am Fam Physician*. 2005 Aug 15; 72(4):623-30.
8. Bindra A, Braunstein GD. Thyroiditis. *Am Fam Physician*. 2006 May 15; 73(10):1769-76.
9. Nguyen GK, Lee MW, Ginsberg J, Wragg T. Fine-needle aspiration of the thyroid: an overview. *CytoJournal* 2005; 2:12
10. McCaffrey TV. Evaluation of the Thyroid Nodule... *Cancer Control* 2000; 7:223-228.
11. Bisi H, Ruggeri GB, Longatto Filho A, de Camargo RY. Neoplastic and non-neoplastic thyroid lesions in autopsy material: historical review of six decades in Sao Paulo, Brazil. *Tumori*. 1998 Jul-Aug; 84(4):499-503
12. Ahmad M, Malik Z, Janjua SA. Surgical audit of solitary thyroid nodule. *Pak Armed Forces Med J* 2001; 51: 106-10.
13. Prescott E, Netterstrom B, Faber J, et al. Effect of occupational exposure to cobalt blue dyes on the thyroid volume and function of female plate painters. *Scand J Work Environ Health* 1992; 18:101
14. Gaitan E. Goitrogens. *Baillieres Clin Endocrinol Metab* 1988; 2:683-702
15. Gaitan E. Goitrogens in food and water. *Annu Rev Nutr* 1990; 10:21-39
16. Ingenbleek Y, De Visscher M. Hormonal and nutritional status: critical conditions for endemic goiter epidemiology? *Metabolism* 1979; 28:9-19
17. Lamberg BA. Endemic goitre—iodine deficiency disorders. *Ann Med* 1991; 23:367-72
18. Ahmed I, Malik ML, Ashraf M. Pattern of malignancy in solitary thyroid nodule. *Biomedica* 1999; 15: 39-42.
19. Sarfraz T, Khalilullah M, Muzaffar M. The frequency and histological types of thyroid carcinoma in northern Pakistan. *Pak Armed Forces Med J* 2000; 50: 98-101.
20. Qureshi N, Jaffer R, Ahmed N, Nagi AH. Causes of goitre. *Biomedica* 1996; 12: 54-56.
21. Ambreem A Imran, Sarosh Majid, Saeed Akhtar Khan. Diagnosis of enlarged thyroid - an analysis of 250 cases. *Ann King Edward Med Coll Sep* 2005; 11:203-4.
22. Bindra A Braunstein GD. Thyroiditis. *Am Fam Physician*. 2006; 73:1769-76.
23. Rosai J. *Akerman's Surgical Pathology* (9<sup>th</sup> edition). New dehli, Mosby. 2004; 512-613.