

Automated Detection of Malaria: A Comparison with Microscopy

S FADLALLA ALI S JAMIL M N AKHTAR *M FAROOQ

Department of Hematology, Central laboratory and Blood Bank, Riyadh, Saudi Arabia. *Blood Bank, Lady Aitchison Hospital, Lahore
Correspondence to Dr. Sajid Jamil (drsajid19@hotmail.com)

Objective: To compare the automated detection of malaria with microscopy. **Methods:** In this study 250 blood samples submitted for malaria investigation were studied microscopically for malaria parasites. All samples were additionally analyzed for same parameters with automated hematology analyzer, Cell Dyn 3700 (CD3700). The results from the instrument generated as scatter plots (derived by laser light depolarization), were compared with microscopy results.

Results: The atypical depolarizing events or positive patterns were observed in 43 out of 250 samples on cell Dyn 3700, while microscopically 37 samples were found to be positive. Three samples positive on microscopy, were found to be negative on CD-3700. Compared with microscopy the sensitivity of CD3700 was 92.5% and specificity was 97.3%. Maximum parasitaemia was 6.5%. **Conclusions:** Automated detection of malaria by CD3700 automated hematology analyzer is feasible for screening purpose in malaria endemic and non-endemic areas.

Key words: Malaria. Atypical depolarization pattern, *P. falciparum*, *P. vivax*, parasitaemia

Malaria is one of the serious diseases of underdeveloped world, currently affecting 300-500 million people each year, with a mortality rate of 1%¹. It is endemic in parts of Asia, the Middle East, Africa, Central and South America and is primarily found in hot and humid environment which is ideal for breeding of anopheles mosquito². Malaria is caused by infection with one or more of four species of *Plasmodium* (i.e., *P. falciparum*, *P. vivax*, *P. ovale*, and *P. malariae*). The infection is transmitted by the bite of an infective female *Anopheles* mosquito, blood transfusion or using shared common syringes³.

Following the infective bite of *Anopheles* mosquito, symptoms appear after the incubation period which varies from 7 to 30 days. Sporozoites injected by the mosquito are carried to the liver where they multiply and are released from hepatocytes into blood stream to infect red blood cells².

Malaria is usually presented with fever, headache, back pain, chills, increased sweating, myalgia, nausea and vomiting. Untreated *P. falciparum* infections can rapidly progress to coma, renal failure, pulmonary edema, and death. Asymptomatic parasitaemia can occur, most commonly among persons who have been long term residents of malarious areas⁴. The main hematological findings in patient's blood are anemia, thrombocytopenia, variable total leukocyte count and parasitaemia⁵.

Although malaria is not found in urban areas of Saudi Arabia but anopheles breeding sites still exists in oasis and coastal regions. Imported cases of malaria are seen in expatriate work force after returning from their home countries where it is endemic⁶.

Materials and Methods

Two hundred and fifty adult subjects suspected of malaria were selected from Riyadh Medical Complex. Twenty normal control subjects were also included (thick and thin smears negative for malaria). Only those patients were considered positive where malaria parasites were found on microscopy. Thick and thin films were prepared and stained with Giemsa stain⁷. Thick films were used for

detection and quantification while thin films for identification of species⁸.

Controls, negative and positive samples were run in Cell-Dyne 3700 and their pattern of depolarization were studied and compared with each other. All cases found positive on microscopy were considered true positive.

In Cell Dyne 3700, white cell populations are initially subdivided into mononuclear and polynuclear fractions, based on differential 10° (complexity) and polarized 90° (lobularity) light scattering properties. The 90° depolarized light scatter channel separate eosinophils from neutrophils. Normally granulocytes do not depolarize light except eosinophils. Malaria parasites in monocytes produce haemozoin, which is able to depolarize light, producing abnormal depolarizing events. This allows the automated detection of malaria during routine complete blood count analysis. Scanty and abundant diagnostic depolarizing events correspond to degree of parasitemia⁹.

Results:

In this study *P. falciparum* and *P. vivax* were identified in blood films from 34(92%) and 3(8%) infected persons respectively. Maximum parasitemia was found to be 6.5% while 0.1% was the minimum. There were 8(21.6%) patients who have parasitemia of 1% or above.

Out of 250 patients, 37(14.8 %) were diagnosed microscopically as malaria positive, 43(17.2%) showed the atypical depolarization patterns by Cell Dyn 3700, which were not found in control subjects. Six patients out of 43 showed atypical depolarization pattern which were proved to be negative (false positive) on microscopy. These false positive samples showed only one or two isolated abnormal depolarizing events, whereas true positive cases showed two or more abnormal depolarizing events.

Normal depolarization pattern is shown in Fig. 1, while light scatter pattern of typical malaria positive result is shown in figure 2. The presence of two or more events identified as large mononuclear cells with 90° depolarized signal in excess of the 90° polarized (above the 45° line) light were found to be strongly associated with a diagnosis

of malaria. Over all sensitivity and specificity for automated detection of malaria by CD3700 was 92.5% and 97.3 respectively.

Table Comparison of malaria parasites with microscopy

	MP +ve	MP -ve	Total(n)
Microscopy	37	213	250
Cell Dyn 3700	43	207	250

MP= Malaria parasite

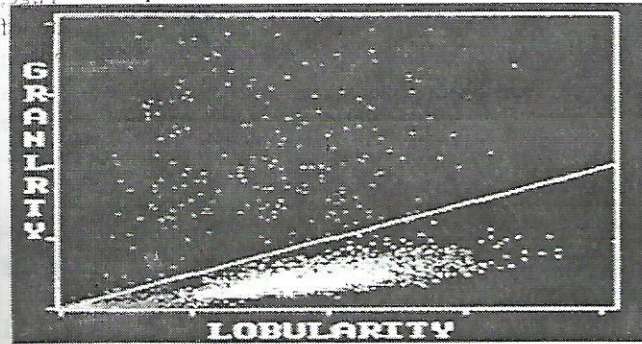
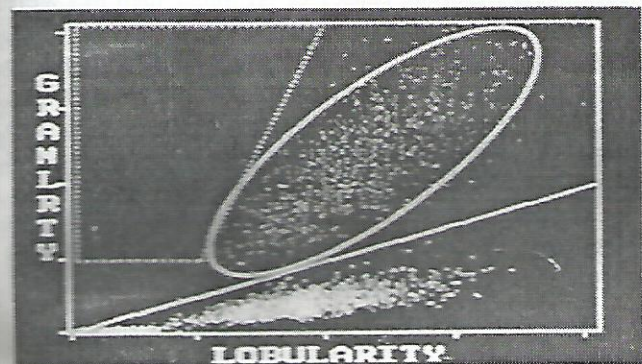


Fig 1: Malaria sample showing abnormal depolarising events that are not in the position normally associated with eosinophils.

Fig 2: Granularity (90° depolarisation axis) versus Lobularity (90° polarisation axis) plot. Eosinophils are located within the area demarcated by the oval line, while the atypical depolarisation region is indicated by the broken line, does not normally contain any events.



Discussion:

Patients with fever, malaise and anemia, especially in non-endemic areas are not usually/ rarely investigated for malaria. The physician often advises initial general screening tests including complete blood count (CBC). The malaria parasites identification on peripheral smear examination is often missed because it is not routinely stressed and also due to lack of awareness and special training, especially in non- endemic areas. Microscopy is especially unreliable in cases of low parasitemia and is also dependent on high index of suspicion⁹. The screening CBC has become throughout the world a rapid and inexpensive yet valuable component in the diagnostic investigation of any patient and particularly the patient with pyrexia of unknown origin.

In the present study, automated hematology analyzer was found useful for screening and detection of malaria as

the sensitivity and specificity of the CD3700 is 92.5% and 97.3 % respectively, when compared with microscopy.

Malaria pigment has birefringent property which is used for the automated detection of malaria¹⁰. Haemozoin is produced by all species of plasmodia. Intra leucocyte haemozoin is present in approximately 90% of the patients with malaria¹¹. Following successful treatment and parasite clearance, there is convalescent phase in which haemozoin persists, resulting in false positive malaria by CD3700. Similarly false negative malaria could result in early period as production and accumulation of haemozoin lags behind parasite expansion. Chloroquine inhibits haemozoin production in chloroquine sensitive *P. falciparum*¹².

The finding of atypical depolarization in hematology analyzers could have major role in large scale diagnostic screening and surveillance programmes especially in malaria endemic areas. This technology is particularly useful in countries like Saudi Arabia where significant number of people regularly come from malaria endemic regions of the world.

References:

1. World Health Organization. World malaria situation in 1994. *Wkly Epidemiol Rec* 1997; 72:269-76.
2. Michael JGF. Infectious diseases, tropical medicine and sexually transmitted diseases. In: Kumar P and Clark M. *Clinical Medicine*. 4th ed. London: WB Saunders. 1998;77.
3. Causer LM, Newman RD, Barber AM, Robert JM, Stennies G, Poland PB et al. Malaria surveillance- United States, 2002. In: *CDC Surveillance Summaries* (July 12, 2002). *MMWR* 2002;51(No.SS-5):9-23.
4. Filler S, Causer LM, Newman RD et al. Malaria surveillance-United States, 2001. In: *CDC Surveillance Summaries* (July 18, 2003). *MMWR* 2003; 52(No.SS-5):1.
5. Mohapatra MK, Mitra I. Haematological and coagulation profile in malaria. *The Indian Practitioner* 2002; 55(2): 75-8.
6. Niazi GA. Hematological aspects of malaria in a population based hospital, Saudi Arabia. *J Egypt Soc Parasitol* 1995; 25(3):787-93.
7. Dacie JV Preparation and staining methods for blood and bone marrow films. In: Dacie JV, Lewis SM. *Practical Haematology* 9th ed: Churchill Livingstone 2001:55-56.
8. Diagnostic procedures for blood specimens. Laboratory identification of parasites of public health concern. Diagnostic procedure. Centre for disease control and prevention. 22.6.2004.
9. Mendelow BV, Lyon C, Nilhangothi P, Tana M, Munster M, Wypkema E et al. Automated malaria detection by depolarization of laser light. *Br J Haematol* 1999; 104: 4993.
10. Lawrence C and Oslen JA. Birefringent hemozoin identifies malaria. *AJCP* 1985;86:360-63. 11.
11. Scott CS, Van Zyl D, Ho E, Meyersfeld D, Ruivo L, Mendelwo BV et al. Automated detection of malaria associated intraleucocytic haemozoin by Cell Dyn CD 4000 depolarization analysis. *Clin Lab Haematol* 2003; 25(2):77.
12. Scott CS, Van Zyl D, Ho E, Ruivo L, Kunz D, Coetzer TL. Pattern of pseudo-reticulosis in malaria: Fluorescent analysis with the Cell Dyn CD 4000. *Clin Lab Haematol* 2002; 24:15-20.